



PROTECTIVE EFFECT OF *CHENOPODIUM ALBUM* ETHANOLIC EXTRACT AGAINST ASPIRIN INDUCED PEPTIC ULCER IN RAT MODEL

Pavan Kumar Padarthy¹, K Jagatheesh¹, Kowsalya R¹, C Muneer Babu²,
Elangovan Namasivayam^{1*}

^{*1}Department of Biotechnology, Periyar University, Salem, Tamilnadu, India.

²Department of Pharmacy, Annamalai University, Chidambaram, Tamilnadu, India.

ABSTRACT

Chenopodium album, is a commonly used plant in Indian traditional medicine belongs to family *Chenopodiaceae*. In our study, anti-ulcer activity of its ethanolic extracts of whole plant were investigated using Wistar rats as animal models. Extracts were also subjected to phytochemical analysis and found to contain Carbohydrates, Proteins, Flavonoids, Tannins and phenolic compounds. *Chenopodium album* alcoholic extracts were found to be non-toxic up to 1500 mg/kg dose level. During confirmation of the claimed anti-ulcer activity, treatment with two different alcoholic extracts in 200mg and 400 mg/kg showed significant reduction in ulcer index, free acidity as well as total acidity in pylorus ligated rats. However, profound reduction in all these indices was observed with both of the doses. But higher dose of extract showed relatively significant protection.

Key words: *Chenopodium album*, Ulcer index, Antiulcer activity.

INTRODUCTION

Peptic ulcer is an open crater or sore that develop in the inner lining (mucosa) of the stomach or the duodenum. A coating of mucus and other chemicals normally shields the stomach and duodenum from digesting themselves. When these protective mechanisms are disrupted, powerful digestive acids can erode into the lining of these organs and cause peptic ulcer (Anonymous 1; Tripathi KD, 2003). A peptic ulcer may arise at various locations like Stomach (called gastric ulcer), Duodenum (called duodenal ulcer), Esophagus (called esophageal ulcer), A Meckel's diverticulum was shown in Fig.1:

Treatment of peptic ulcer (Satoskar RS *et al.*, 2008; Roger Walker *et al.*, 2006; Maity S *et al.*, 1995)

Reduction of gastric acid secretion

H₂-antihistamines – Cimetidine, Ranitidine, Famotidine, Roxatidine, Loxatidine.

Proton pump inhibitors – Omeprazole, Lansoprazole, Pantoprazole, Rabeprazole, Esomeprazole.

Anticholinergics – Pirenzepine, Propantheline, Oxyphenonium.

Prostaglandin analogues – Misoprostol, Enprostil, Rioprostil.

Neutralization of gastric acid (antacids)

Systemic- Sodium bicarbonate, Sodium citrate.

Non systemic-Magnesium hydroxide, Magnesium trisilicate, Aluminium hydroxide gel, Magaldrate, Calcium carbonate.

Ulcer protectives- Sucralfate, Colloidal bismuth subcitrate (CBS).

Ulcer healing drugs- Carbenozolone Sodium.

Anti H-Pylori drugs- Amoxicillin, Clarithromycin, Metronidazole, Tinidazole, Tetracycline.

Chenopodium album

Chenopodium album L. var. *album* Family *Chenopodiaceae* distributed throughout India, in areas

Corresponding Author

Elangovan Namasivayam

Email: elangovannn@gmail.com

upto 4,200m elevation, wild as well as cultivated. The plant is a small odourless herb upto 3.5m in height, erect or ascending, stems often stiped, leaves simple, very variable, upto 15 cm long, oblong, deltoid or lanceolate, obtuse (or) acute, entire, toothed or irregularly obulate, flowers in clusters in spikes, fruits membranous utricle, enclosed in the perianth, seeds smooth, shiny, compressed.

Properties and uses

The plant is sweet, acrid, oleaginous, digestive, carminative, laxative, anthelmintic, diuretic, aphrodisiac and tonic and is useful in vitiated conditions of pitta, peptic ulcer, helminthiasis, dyspepsia, splenopathy, haemorrhoids, ophthalmopathy, cardiac disorders and general debility.

MATERIALS AND METHODS

Preparation of Ethanolic Extract

The 100 gm of dried powder of whole plant was loosely packed in the thimble of soxhlet apparatus and was extracted with following solvents successively Petroleum Ether (60-80°C) for 24 hrs - Ethanol (78 - 85°C) for 24 hrs - Distilled water (100°C) for 24 hrs. A series of extraction was carried out with the above solvents simultaneously for obtaining better extract. From these extract only ethanol was selected for further study. The extract was then concentrated by evaporating the solvent. The Concentrated extract was air dried at room temperature, weighed and percentage yield was calculated. The colour and consistency of the extract was noted. The semisolid form of the extract was insoluble in water; to make the extract soluble an inert solubilizer 1% CMC was used.

Experimental Animals

Wister strain rat's adult of either sex. Each rat that weighed between 180-200 gm was housed separately. The rats were divided randomly into 5 groups of 6 rats each. The animals were left for 48 hrs to acclimatize to the animal room conditions. They were maintained in standard laboratory conditions of temperature 22±2°C, humidity, 12 hours light and dark cycles fed with standard pellet diet and tap water.

Thirty rats were divided into five groups of six animals each.

Group I: Control (Carboxy methyl cellulose 1ml/kg b.w) for 4 days P.O.

Group II : Ulcer control (Aspirin 200 mg/Kg) for 4 days P.O.

Group III : Test I lower dose (200 mg/Kg ethanolic extract of *Chenopodium album*) for 4 days P.O + Aspirin (200 mg/Kg) on 4th day P.O.

Group IV : Test II higher dose (400 mg/Kg ethanolic extract of *Chenopodium album*) for 4 days P.O + Aspirin (200 mg/Kg) on 4th day P.O.

Group V : Standard drug (Ranitidine 20 mg/kg) for 4 days P.O + Aspirin (200 mg/kg) on 4th day P.O.

On 4th day 4 hrs after administration of ulcerogen animals were sacrificed by cervical dislocation. The stomach were removed and opened along the greater curvature and the gastric juice were collected and separated, gastric lesions were observed using dissecting microscope. Mean ulcer score for each animal was expressed as ulcer index. The stomachs were then fixed in 10% buffered formalin solution for histopathological studies (Kulkarni S K *et al.*, 2010).

Collection of Gastric Juice

The stomach was excised carefully keeping the esophagus closed, opened along the greater curvature and the gastric contents were removed. The gastric contents were collected in plain tubes and centrifuged at 3000 rpm for 5 min; the volume of the supernatant was expressed as ml/100 gm body weight. The mucosa was flushed with saline and observed for gastric lesions using a dissecting microscope, ulcer score was determined (Kulkarni S K *et al.*, 2010).

Ulcer Scoring

After sacrificing the rat, stomach was removed and opened along the greater curvature, and washed it slowly under running tap water. Put it on the glass slide and observe under 10X magnification for ulcer. Score the ulcers as 0 = normal coloured stomach, 0.5 = red colouration, 1 = spot ulcers, 1.5 = haemorrhagic streaks, 2 = Ulcers ≥ 3 but ≤ 5, 3 = Ulcers >5.

Free acidity and Total acidity

Centrifuge the gastric contents at 10000 rpm for 10 min, note the volume pipette out 1 ml of supernatant liquid and dilute it to 10 ml with distilled water. Note the P^H of the solution with the help of P^H meter. Titrate the solution against 0.01N NaOH using topfers reagent as an indicator, titrate to end point when the solution turns to orange colour. Note the volume of NaOH which corresponds to free acidity. Titrate further till the solution regains its pink colour. Note the total volume of NaOH which corresponds to the total acidity (Malairajan P *et al.*, 2007). Acidity (mEq/1/100 g) can be expressed as

$$\text{Acidity} = \frac{\text{Volume of NaOH} \times \text{Normality} \times 100}{0.1} \text{ mEq/1/100 g}$$

Histopathological study

The stomach were washed thoroughly with saline and small pieces were collected in small bottles containing 10% formalin solution and were subjected to stomach biopsies were processed and assessed for damage

by taking a 5 μ m section, stained with Hematoxylin and Eosin and analyzed under light microscopy (Sairam K *et al.*, 2003).

RESULTS

Preliminary Phytochemical Analysis of Extract

The Ethanolic extract of whole plant of *Chenopodium album* containing phytochemical constituents such as Carbohydrates, Proteins, Flavonoids, Tannins and phenolic compounds (Table.1). The results of phytochemical testing were summarized below. The test drug did not show any signs of toxicity or mortality up to 4000 mg/Kg and hence the LD₅₀ of Ethanolic extract of *Chenopodium album* could not determine. At a dose of 4000mg/kg the drug produced mortality and the rate of death increased as the dose increased up to 5000mg/kg. The test drug is an herbal extract and not completely dissolved in water therefore, a suspension of the test drug was made using 1% Tween 80. It could not possible to enhance the dosage further as it was not suspended in required volume of distilled water. The dose upto 4 g/Kg orally in rat is safe and practically non-toxic. Hence, Ethanolic extract of *Chenopodium album* can be assumed to be free from toxicity up to 4g/kg. Thus the dose of 4000mg/kg was selected as the maximum tolerated dose.

Antiulcer Studies

Administration of aspirin resulted in severe erosions in all the animals treated. However daily administration of Ethanolic extract of *Chenopodium album* for 4 days and aspirin on 4th day did not show any gastric erosions when compared to ulcer control rats that received aspirin for 4 days. Ranitidine, the standard reference drug also did not show increased gastric erosions as compared to the ulcer control rats. Administration of aspirin results in the formation of haemorrhagic erosions. While pretreatment of Ethanolic extract of *Chenopodium album* and rats treated with Ranitidine significantly reduced the formation of haemorrhagic erosions in comparison with control rats treated with Aspirin. Grossly, from the results of the current study showed that pretreated rat with *Chenopodium album* whole plant extract for 4 days or Ranitidine significantly reduced the formation of gastric ulcer induced by aspirin compared to ulcer control

groups. Also animals pretreated with Ethanolic plant extract significantly reduced the gastric lesion compared to rats treated with aspirin was shown in Table.2.

Effect of Free Acidity and Total Acidity

The free acidity and total acidity was determined based on the titre values. The free acidity and total acidity decreased significantly in comparison with the standard group (Group-V) treated with ranitidine (Table.3).

Ulcer index

The ulcer index was calculated by taking the mean ulcer score of each groups. Then the mean ulcer score graph was plotted with groups on x-axis and ulcer index on y-axis. The histograms of different groups were then interpolated by comparing the ulcer index of group I with group II, III, IV and V. and group II with III, IV and V. It was noticed that the index of test group (test-3 and 4) was significantly less when compared to the standard group (Group-V) treated with ranitidine.

MACROSCOPICAL VIEW OF RAT STOMACH

After mounting the rat stomach on glass slide and observed in 10x magnification different scores were noted in each groups. The mean ulcer score represents the ulcer index. The scores on each group were compared, ie group I with group II, III, IV and V and group II with III, IV and V. Group III and IV were having similar ulcer score as that of group V.

Histopathological Study

Histologically rats, pretreated with Ethanolic extracts of *Chenopodium album* for 4 days or Ranitidine also significantly inhibited the gastric lesion formation and submucosal edema, induced by aspirin compared to animals pretreated with CMC. Animals pretreated with Ethanolic extract significantly inhibit the formation of gastric lesion and mild submucosal edema as similar to animals pretreated with Ranitidine. Group I shows normal mucosa with no ulcer while Group II shows ulcerated mucosa with hemorrhagic erosions showing discontinuity in the lining of epithelium cells. Group III and Group IV shows normal mucosa with mild edematous submucosa and mild hyperplasia respectively. Group V showing normal mucosa with small strophic gland, mild hyperplasia and no edema.

Fig 1. Ulcer Affecting Locations of Gastro intestinal tract

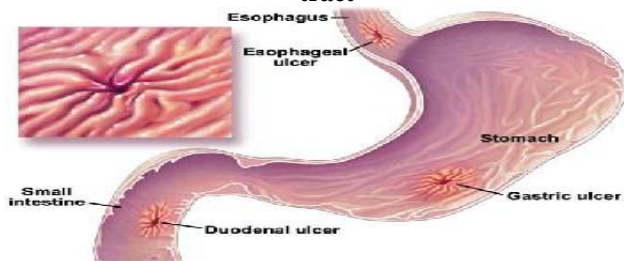


Fig.2 *Chenopodium album* plant



Fig 3. Effects of Total Acidity

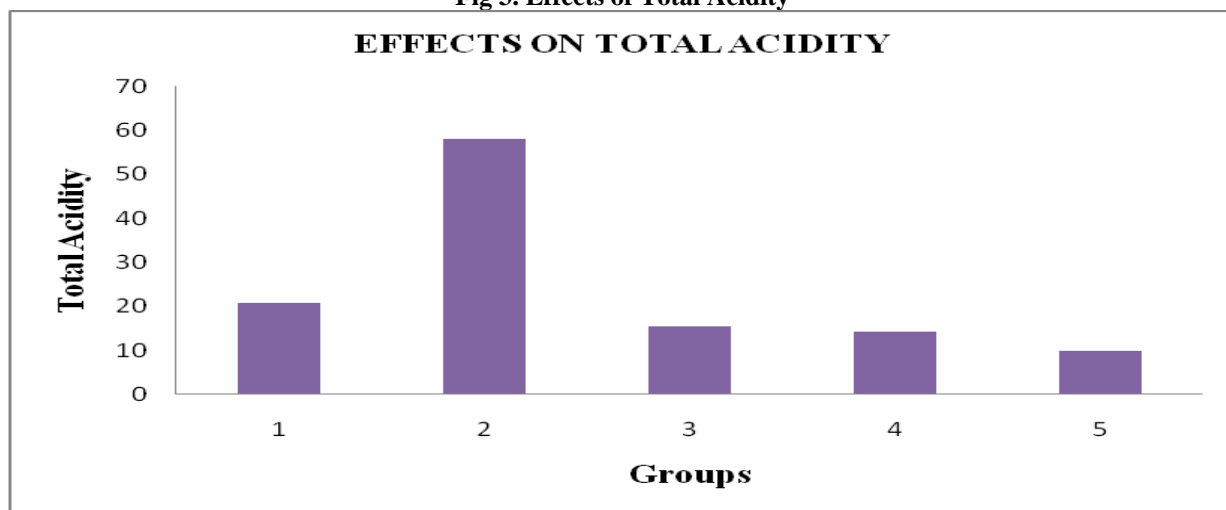


Fig 4. Macroscopical View of Rat Stomach

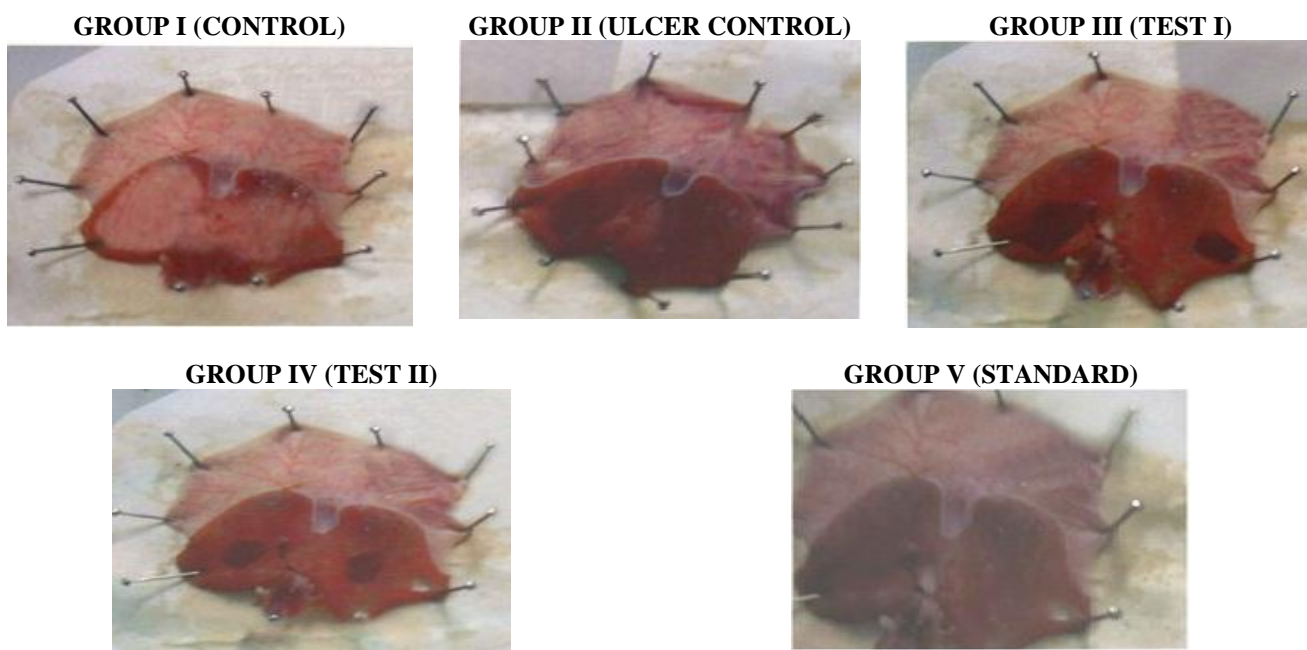
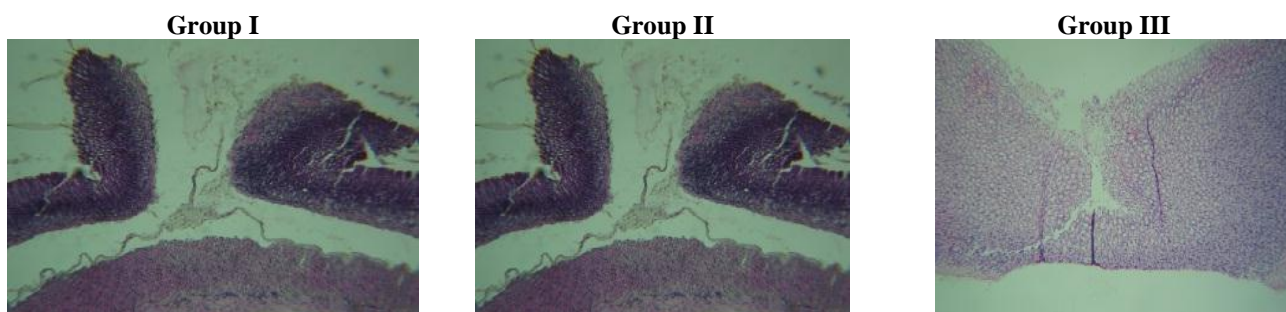


Fig 5. Histopathological View of Stomach Mucosa Section



**Table 1. Preliminary Phytochemical testing of Extract**

S.No	Test/reagent	Ethanollic Extract of whole plant of <i>Chenopodium album</i>
1	Steroids	Salkowski --
2	Alkaloids	Dragendroff's test --
		Hager's test --
		Mayer's test --
		Wagner's test --
3	Saponins	Foam test --
4	Fats and Oils	Filter paper test --
5	Tannins and Phenolic compounds	Ferric chloride Test ++
		Lead acetate test ++
		Pot. Dichomate --
		Bromine water --
6	Flavonoids	Shinoda test ++
		Lead acetate test ++
7	Carbohydrates	Molisch test ++
		Fehling's test ++
		Barfoed's test --
8	Proteins	Millon's test --
		Biuret test ++
9	Amino acid test	Ninhydrin test --

+ Ve indicates the presence of compounds. - Ve indicates the absence of compounds.

Table 2. Effect of ethanolic extract of *Chenopodium album* on gastric volume

S.No	Groups	Volume of Gastric juice
1	Group I	2.34±0.226
2	Group II	3.3±0.400
3	Group III	2.08±0.426 a**b**
4	Group IV	1.52±0.214a*b*
5	Group V	2.13±0.432

Values are expressed in terms of mean ± SEM of 6 rats using ANOVA a → Group I compared with groups II, III, IV and V, b → Group II compared with groups III, IV and V. P values: * < 0.001 - Highly significant, ** < 0.05 - Significant, N S: Non Significant

Table 3. Effect of ethanolic extract of *Chenopodium album* on free acidity and total acidity

S.No	Groups	Acidity	
		Free	Total
1	Group I	11±2.61b*	20.83±3.06b*
2	Group II	28.67±4.89a*	58.17±5.49a*
3	Group III	7.50±1.87b*	15.50±3.78b*
4	Group IV	6.50±1.87a**b*	14.33±3.50 a**b*
5	Group V	8.33±1.51b*	9.83±3.82a*b*

Values are expressed in terms of mean ± SEM of 6 rats using ANOVA a → Group I compared with groups II, III, IV and V, b → Group II compared with groups III, IV and V, P values: * < 0.001 - Highly significant, ** < 0.05 - Significant, N S: Non Significant.

Table 5. Effect of ethanolic extract of *Chenopodium album* on Ulcer index

S.No	Groups	Group I	Group II	Group III	Group IV	Group V
1	Ulcer Index	2.2±1.45	3.75±1.47	2±0.775 b**	1.17±0.98 a** b**	2.25±0.82

Values are expressed in terms of mean ± SEM of 6 rats using ANOVA a → Group I compared with groups II, III, IV and V, b → Group II compared with groups III, IV and V P values: * < 0.001 - Highly significant, ** < 0.05 - Significant, N S: Non Significant

DISCUSSION

It is evident from the result of the present investigation that the Ethanolic extract of *Chenopodium album* possesses antiulcer activity in aspirin induced acute ulcer model. It has shown a significant reduction in the gastric lesions of the aspirin treated animals. Although the etiology of gastric ulcer is not known in most cases, it is generally accepted that it results from an imbalance between aggressive factors and the maintenance of mucosal integrity through the endogenous defense mechanisms. To regain the balance, different therapeutic agents including plant extracts are used (in experimental animals) to inhibit the gastric acid secretion or to boost the mucosal defense mechanisms by increasing mucus production, stabilizing the surface epithelial cells/or enhancing prostaglandin synthesis. Ranitidine the H₂-antihistamines play an important role in the reduction gastric volume and total acidity and thus perform a cytoprotective effect. In the present study, the marked reduction in the volume of gastric secretion and total acidity associated with aspirin induced ulceration support the suggestion that acidity or gastric secretion (considered as aggressive factors for ulceration) may not play major role in the ulcer induced by aspirin. The present results demonstrate that the Ethanolic extract of *Chenopodium album* protect the rat gastric mucosa against hemorrhagic lesion produced by aspirin.

The cytoprotective effect was confirmed by histological examination showing prevention of mucosal lesions and submucosal edema. Aspirin induced method of gastric lesions is rapid and convenient way of screening plant extracts for antiulcer potency and cytoprotection in macroscopically and microscopically visible lesions. Aspirin induced gastric ulcer has been widely used for the experimental evaluation of antiulcer activity. Aspirin induced gastric lesion formation may be due to stasis in gastric blood flow, which contributes to the development of the hemorrhagic and necrotic aspect of tissue injury. It is of interest to note that administration

of antioxidants inhibit aspirin induced gastric injury in the rats. Ethanolic extract of *Chenopodium album* may possess significant antioxidant activity.

The flavonoids are likely that the antioxidant property of the *Chenopodium album* could be linked to its gastroprotective effect. It could be conceived that *Chenopodium album* ethanolic extract exert their antiulcer activity through the flavonoids since flavonoids are reported to protect the mucosa by preventing the formation of lesions by various necrotic agents. These results suggest that *Chenopodium album* whole plant extract could be beneficial component of preventing ulcer formation induced by aspirin. In conclusion, the antiulcer effects of plant appeared to have several important properties that make it useful ideal as a remedy for antiulcer, We can suggest that it may be possible to use plant extract as remedy to prevent ulcers. However, further investigations are required to elucidate their exact mechanism of antiulcer activity.

CONCLUSION

From the results discussed above it can be summarized that the Ethanolic extract of *Chenopodium album* possesses the antiulcer activity against the aspirin induced gastric ulceration in rats as animal model. The phytochemical results revealed that the plant extract containing flavonoids, tannins, polyphenolic compounds. Also the plant's Ethanolic extract has wide range of safety. It does not show any signs of toxic effects in treated mice as well as rats. Aspirin produces severe erosions. It produces ulcers through mucosal damage. Pretreatment of Ethanolic extract of *Chenopodium album* preventing the mucosal damage resembles that of Ranitidine, induced by the aspirin. It can be concluded that the plant extract may shows antiulcerogenic activity due to the presence of flavonoids. The plant extract also shows the cytoprotection. Further evaluation and study is necessary about *Chenopodium album* as an important medicinal plant.

REFERENCES

- Anonymous 1. www.pepticulcermerckmanual.html.
 Kulkarni S K. Hand book of Experimental Pharmacology, 3rd revised and enlarged edition, 2010, 149.
 Maity S, Vedasiromoni S J R and Ganguly D K. Anti-ulcer effect of the hot water extract of black tea (*Camellia sinensis*), *Journal of Ethnopharmacology*, 46(3), 1995, 167-174.
 Malairajan P, Geetha Gopalakrishnan, Narasimhan S, Jessi Kala Veni K and Kavimani S. Anti-ulcer activity of crude alcoholic extract of *Toona ciliata* Roemer (heart wood), *Journal of Ethnopharmacology*, 110(2), 2007, 348-351.
 Roger Walker and Clive Edwards, Ray Sahelian. Clinical pharmacy and therapeutics. stomach and Peptic ulcer, herbs, natural options, research update supplements, 3rd edition, Year-2006.

- Sairam K, Priyambadas, Aryya NC, Goel RK. Gastro-duodenal, ulcer protective activity of *Asparagus racemosus*, an experimental, biochemical and histological study. *J. Ethnopharmacol*, 86, 2003, 1-10.
- Satoskar R S, Bhandarkar S D, Ainapure S S. *Pharmacology and pharmacotherapy*, Revised 17th edition, 2008.
- Tripathi KD. *Essentials of Medical pharmacology*, *Jaypee brother's medical publishers (P) Ltd.* 5th edition, Year 2003.