



WOUND HEALING ACTIVITY OF *TERMINALIA ARJUNA* IN ALBINO WISTAR RATS

Hemah Devi^{1, 2†}, Shankar Jothi^{1, 2}, Ishwin Singh^{1, 2}, Vetriselvan Subramaniam^{2*},
Gayathiri Silvarajah^{1, 2}, Shereenjeet Kaur^{1, 2}, Yaashini Annamalai^{1, 2}

¹ Faculty of Science Technology and Engineering, La Trobe University, Bendigo, Australia.

² Faculty of Pharmacy, Masterskill University College of Health Sciences, Selangor, Malaysia.

ABSTRACT

Wound is defined as loss and breaking of anatomic and cellular of living tissue. Wound healing process is a biological process instigated by trauma and causes scar formation. *Terminalia arjuna* is a deciduous tree of the Combretaceae family served as native Ayurvedic medicine in India. The aim of the study is to evaluate the wound healing activity in animal model and also to study the pharmacological action of *Terminalia arjuna* extract compared to standard drug in wound healing activity. Plant material was prepared into preparation of 50% ethanolic extract. An excision wound made on the depilated back of the rat. Epithelialization period was noted as the number of days after wounding required for the eschar to fall off leaving no raw wound behind. Wound contraction rate was monitored by planimetric measurement of the wound area on alternate days for 21 days. These sections of tissue collected were stained with Van Gieson. After staining, the sections were observed under light microscope for histopathological changes. The significant ($P < 0.001$) shows decrease in wound size on day 21 compared to day 0 for standard drug, Dexamethasone and *Terminalia arjuna* 400mg treated rat confirmed the good wound healing activity of *Terminalia arjuna* in the group of rats. From the results attained in present investigation, it is feasible to conclude that the tree bark extract of *Terminalia arjuna* which contains active constituent, tannin has significant wound healing activity at the doses tested.

Key words: *Terminalia arjuna*, Dexamethasone, Wound contraction, Wound healing, Histopathological study.

INTRODUCTION

Wound is defined as loss and breaking of anatomic and cellular of living tissue. Wound healing process is a biological process instigated by trauma and causes scar formation. Wound healing process occurs in few different stages such as coagulation, epithelisation, granulation, collagenation and remodelling of tissue. Wound healing is an active and multifaceted process in restoring cellular structures and tissue layers. The objective of wound management is to heal the wound in express time possible, with very nominal pain, discomposure and scarring in patient with wound. At the

site of closure, a lithe and fine scar with high tensile strength is required (Bairy *et al.*, 2001).

Terminalia arjuna is a deciduous tree of the Combretaceae family found in India, Sri Lanka, Burma and Mauritius. The extract of this plant served as native Ayurvedic medicine in India. The primary herbal remedy comes from its' tree bark and fruit that formed by the tree. Medically, *Terminalia arjuna* can be used in the treatment of wound healing, to treat inflammation (Alam Morshed M *et al.*, 2011) coronary artery disease, heart failure and hypercholesterolemia. *Terminalia arjuna* can be used in treatment of dermatological where it is used in fractures, inflammation, wounds and ulcers. Patient with cancer, gynaecological complaints, heart disease tend to use *Terminalia arjuna* for their treatment.

Improvement in cardiac muscle function of the heart is the primary benefit of *Terminalia arjuna* (saponin glycosides). The flavonoid provides free antioxidant

Corresponding Author

C Hemah Devi

Email: vaasigurl_88@yahoo.com

activity and vascular strengthening. Arjuna tree is a pest and disease free tree. It has buttressed trunk that is enormous and horizontally dissemination branches. The bark is pinkish-grey in colour which flakes off in big chunks, arched and flat pieces. *Terminalia arjuna*'s active constituents are including tannin, flavonoids (Gupta R *et al.*, 2001) triterpenoid saponins, gallic acid, ellagic acid, phytosterols, oligomeric proanthocyanidins, copper, magnesium, calcium and zinc. The aim of the study is to evaluate the wound healing activity in animal model and also to study the pharmacological action of *Terminalia arjuna* extract compared to standard drug in wound healing activity. Therefore an effort has been made to substantiate and institute a systematic support for its ethno botanical uses and construct patient compliant and cost effectual cure. The topical and oral treatment of *Terminalia arjuna*, consisting mainly of tannins, was proved to reveal a greatest enhance in the tensile strength and fastest rate of epithelialization of incision wound. Hexosamine estimation of granulation tissue obtained from excision wounds revealed an increase in the hexosamine content which proves *Terminalia arjuna*'s role in accelerating wound healing process.

AIM AND OBJECTIVE

GENERAL AIM AND OBJECTIVES

To evaluate wound healing activity of *Terminalia arjuna* in albino wistar rats.

SPECIFIC OBJECTIVES

1. To determine wound healing activity of *Terminalia arjuna* extract by evaluating its wound contraction and through histopathological study of the wound tissue.
2. To compare wound healing activity of extract of *Terminalia arjuna* extract and standard drug of Dexamethasone on albino wistar rats.

MATERIALS AND METHOD

The plant material of *Terminalia arjuna* was purchased from Banaras Hindu University Varanasi, for the preclinical evaluation of wound healing activity and further identification has also been done on this plant.

PREPARATION OF EXTRACT

Plant material and preparation of 50% w/v ethanolic extract

The barks of *Terminalia arjuna* were air dried and oven dried at 30°C. The dried barks were then grinded to powder. The plant extract was done based on crude 50% w/v ethanolic extract primed according to the traditional system of medicine. The roughly grinded bark (1kg) was extracted with 50% ethanol (1.5L) for 72 hours (Moulisha Biswas, 2011). Then the extract was distilled and filtered on water bath. Finally the extract was dried at low temperature under low pressure in a rotary

evaporator. A crude residue (75g) was obtained. When required, the crude extract was dispersed in distilled water and used in the study.

CHEMICALS

All chemical reagents used in the study were of R&D grade. All chemicals such as ethanol, formalin, xylene and haematoxylin eosin dye were purchased from Sigma Aldrich Chemical (Singapore). Dexamethasone purchased from local pharmaceutical company were also used in the experiments.

Plant drug(test)	Ethanolic extract of <i>Terminalia arjuna</i>
Standard Drug	Dexamethasone

EXPERIMENTAL ANIMALS

Experiments were carried out on healthy adult male albino wistar rats weighing 200 ± 20 grams. They were raised in the animal house at the Faculty of Pharmacy of the Masterskill University College of Health Sciences. The animals were grouped in polypropylene cages ($38 \times 23 \times 10$ cm) with not more than six animals per cage and maintained under standard laboratory conditions (temperature $25 \pm 2^\circ\text{C}$) with dark and light circle (12/12 h). They were fed a standard diet of pellets and tapped water ad libitum. Rats were routinely adapted to laboratory environment for 7 days subsequent to experiments (Narasimhanaidu Kamalakkannan *et al.*, 2005; Mahuya S *et al.*, 2011). After adaptation, the animals will be subjected to a overall observation, to ensure that the selected animals are in good state of health. The animals were randomly selected for final allocation to the study. Prior authorization for the use of laboratory animals in this study was obtained from the University College Animal Ethical Committee (Reg. MUCH/AEC/HS/2012/16). The experimental procedures were carried out in strict observance with the Animal Ethics Committee's rules and regulations obeyed in this institution.

ACUTE TOXICITY STUDIES

The study was carried on rats as per the guidelines (OECD NO: 423) given by the Organization for Economic Co-operation and Development. Male albino wistar rats ($200 \pm 20\text{g}$) were used for the study. The animals were divided into four groups which consist of three animals each. The extracts were administered separately to the all six animals in each group. The extracts were administered at starting single dose of 5 mg/kg. The rats were observed for 1 hour, intermittently for 3 hours for severity of any rigorous pain sign and mortality. If no mortality is observed at this dose, the similar procedure will be repeated for next day and throughout the study. One group of rats will be administered with standard drug, Dexamethasone 1 mg/kg. If no mortality was observed at this dose, the same

procedure will be repeated for dose level of 50 mg/kg, 400 mg/kg, 2000 mg/kg of extracts. The animals were observed up to 7 days after drug administration to find out any deferred mortality.

Species	Wistar rats
Strain	Albino
Sex	Male
Age	2 - 3 months
Body Weight range	200 ± 20 grams rats
Number of groups	4
Number of animals per group	3
Doses given	5 mg/kg, 20 mg/kg, 400 mg/kg and 2000 mg/kg

WOUND MODELS

The rats will be used to determine the wound healing activity of the plant and standard drug. The depilated back of the rats will be shaved and wound will be caused on their body using excision method. The plant extract will be administered to the rats to evaluate the healing process. All wounding procedures were carried out under ether.

EXCISION WOUND MODEL

An excision wound was inflicted by cutting full thickness of a pre-determined area (2.5 x 2.5cm) on the depilated back of the rat. Epithelialization period was noted as the number of days after wounding required for the eschar to fall off leaving no raw wound behind. Wound contraction rate was monitored by planimetric measurement of the wound area on alternate days (Duarte IDG., 1988). This can be obtained by tracing the wound on a graph paper.

HISTOLOGICAL STUDIES

Slices of tissue from wound from each of the six animals in all groups were preserved in 10% buffered neutral formalin (pH 7.4). The tissues were mounted by Peter Fi's double embedding paraffin sections of 5–10µ size. These sections were then stained with Van Gieson. After staining, the sections were observed under light microscope for histopathological changes and photographs were taken (Escárcega RO., 2007). In excisional biopsy, the entire lesion is removed usually with a rim of normal tissue. Therefore, the procedure serves the diagnostic and therapeutic function. Excising the entire lesion ensures sufficient tissue for histopathological examination, lessen the risk of tumour dissemination and eliminate sampling errors. It is performed when the lesion is smaller in size. Histological technique deals with the preparation of tissue for microscopic examination. The aim of good histological

technique to preserve microscopic anatomy of tissue and make them hard, so that very thin section (4 to 5 micron) can be made. After staining, the section should represent the anatomy of the tissue as close to as possible to their structure in life. This is achieved by passing the total as selected part of the tissue through a series of process. The processes are fixation, dehydration, clearing, embedding, cutting and staining.

FIXATION

Tissue processing is a long procedure and require 24 hours. Tissue processing can be done by manually or mechanically. Mechanical tissue processing (Automatic tissue processors) is used in this study. In this processor, there are different jars containing reagents. These are arranged in a sequence. The tissue is moved from one jar to another by a mechanical device. Timings are controlled by a timer which can be adjusted in respect to hours and minutes. Temperature is maintained around 60°C. The processing, whether manually or mechanically, involves the same steps. The aim of tissue processing is to remove water from tissues and replace with a medium that solidifies to allow thin sections to be cut. Biological tissue must be supported in a hard matrix to allow sufficiently thin sections to be cut, typically 5 µm. Paraffin wax used. Since it is immiscible with water, the main constituent of biological tissue, water must first be removed in the process of dehydration. This is the process by which the constituents of cells and tissue are fixed in a physical and partly also in a chemical state so that they will withstand subsequent treatment with various reagents with minimum loss of architecture. This is achieved by exposing the tissue to chemical compounds, call fixatives. Properties of an ideal fixative are able to prevent autolysis and bacterial decomposition. Preserves tissue in their natural state and fix all components and make the cellular components insoluble to reagent used in tissue processing. The fixative also must be able to preserves tissue volume and avoid excessive hardness of tissue. It should also allow enhanced staining of tissue, non-toxic and non-allergic for user. The fixation can be carried out at room temperature. Tissue should not be frozen once it has been placed in the fixative solution, as a peculiar ice crystal distortion will result. Formalin is available as 40% w/w solution of formaldehyde gas in water. It is used as 10% solution in water or normal saline. It does not precipitate protein but combine with NH₂ group to form an insoluble gel, preserve particularly all elements including fats. It keeps phospholipids insoluble in fat solvents. Tissue can remain in it for prolonged periods without distortion. It is compatible with most special stain.

DEHYDRATION

Tissues are dehydrated by using increasing strength of alcohol; example 50% v/v, 70% v/v, 90% v/v

and 100% v/v. The duration for which tissues are kept in each strength of alcohol depends upon the size of tissue, fixative used and type of tissue. Most tissue specimens may be put into 70% v/v alcohol. Delicate tissue will get high degree of shrinkage by two great concentration of alcohol. The volume of alcohol should be 50-100 times that of tissue.

CLEARING

During dehydration water in tissue has been replaced by alcohol. The next step alcohol should be replaced by paraffin wax. As paraffin wax is not alcohol soluble, we replace alcohol with a substance in which wax is soluble. This step is called clearing. Clearing of tissue is achieved by any of the reagents such as xylene, chloroform, benzene, carbon tetrachloride and toluene. Xylene is commonly used. Small piece of tissue are cleaned in 0.5 to 1 hour, whereas larger (5 cm or more thick) are cleaned in 2-4 hours.

EMBEDDING

Embedding is impregnation with wax. This is allowed to occur at melting point temperature of paraffin wax, which is 54-60 degree. Volume of wax should be about 25-30 times the volume of tissues. The duration of impregnation depends on size and types of tissues and the clearing agents employed. Xylene is easiest way to remove. Total duration of 4 hours is sufficient for routine impregnation. Paraffin wax is used routinely. It has hard consistency, so section of 3-4 micron thickness can be cut. Impregnated tissues are placed in a mould with their labels and then fresh melted wax is poured in it and allowed to settle and solidify. Once the block has cooled sufficiently to form a surface skin it should be immersed in cold water to cool it rapidly.

CUTTING

After the block has completely cooled it is cut into individual blocks and each is trimmed. Labels are made to adhere on the surface of the block by melting the wax with a metal strips sufficiently warmed. The frozen section is a technique in which tissue is frozen rapidly to the temperature of -20 degree centigrade and the sections are cut and stained. In this way tissue can be examined microscopically within 5-10 minutes of its removal from the body. It reduces the time of processing from 18 hours to 5 minutes. It has the disadvantage that only 8-16 micron thick section can be cut and finer details of tissue cannot be examined. Frozen section is performed on a machine called cryostat.

SECTIONING

Vertical sectioning perpendicular to the surface of the tissue is the method used. A steel knife mounted in a microtome is used to cut 5 micrometer thick tissue

sections which are mounted on a glass microscope slide. Then the mounted sections are treated with the appropriate stain.

STAINING

Van Gieson staining is used in this study. The principle of Van Gieson is used to differentiate between collagen and smooth muscle in tumours and to demonstrate the increase of collagen in diseases. The tissue is stained with a regressive hematoxylin, consisting of ferric chloride and iodine. The differentiating is accomplished by using excess mordant (ferric chloride) to break the tissue mordant dye complex. The dye will be attracted to the larger amount of mordant in the differentiating solution and will be removed from the tissue. The elastic tissue has the strongest affinity of the iron hematoxylin complex and will retain the dye longer than the other tissue elements. The procedure of staining done by deparaffinize the tissue section and hydrated to distilled water. The section then dipped into Verhoeff's hematoxylin for 15 minutes and washed in water. For differentiation, place the tissue section in 2% ferric chloride solution and check under microscope for black fibers on a gray background. Then tissue section was rinsed in water and 95 % alcohol momentarily to remove iodine colouration. Washed in water for 5 minutes and counterstain in Van Gieson's for 3 minutes then drain the tissue section. The section was dehydrated rapidly in alcohol, cleared in xylene and coverslip. The results revealed elastic fibers and nuclei in black, collagen in red and other tissue elements in yellow.

STATISTICAL ANALYSIS

Data were expressed as the mean by \pm SD. The data were analyzed using one way analysis of variance (ANOVA) followed by Tukey's test (B. Raghavan., 2006). Data were considered different at significance level ($P < 0.001$).

RESULTS

ACUTE TOXICITY STUDIES

All the rats that received aqueous extract of *Terminalia arjuna* either at high dose up to 2000 mg/kg or low dose were found to be safe. No mortality or toxic symptoms were observed during the entire duration of the study. Ethanolic extract of *Terminalia arjuna* showed a stable compliance towards the rats and proved to be safe.

Figure 1 showed the effect of *T. arjuna* on wound healing activity in male albino wistar rats on 7th day. The control had shown the wound area of 5.65 ± 0.053 . Whereas after administration of *T. arjuna* at the doses of 200mg/kg, and 400mg/kg the value decreased which was 3.33 ± 0.049 and 2.88 ± 0.045 respectively. Treatment of dexamethasone the value was 2.56 ± 0.048 .

Figure 2 showed the effect of *T. arjuna* on wound healing activity in male albino wistar rats on 15th day. The control had shown the wound area of 2.67 ± 0.051 . Whereas after administration of *T. arjuna* at the doses of 200 mg/kg and 400 mg/kg the value decreased which was 1.17 ± 0.046 and 0.82 ± 0.054 respectively. With treatment of dexamethasone the value was 0.61 ± 0.046 .

Figure 3 showed the effect of *T. arjuna* on wound healing activity in male albino wistar rats on 21st day. The control had shown the wound area of 1.42 ± 0.047 . Whereas after administration of *T. arjuna* at the doses of 200 mg/kg, and 400 mg/kg the value decreased which was 0.31 ± 0.047 and 0 ± 0 respectively. With treatment of dexamethasone the value was 0 ± 0 , results from complete wound healing.

Table 1. Effect of ethanolic extract of *Terminalia arjuna* on wound healing activity in albino wistar rats

	7 day	15 day	21 day
Control	5.65 ± 0.05320	2.67 ± 0.05138	1.42 ± 0.04719
200mg	$3.33 \pm 0.04940^*$	$1.17 \pm 0.04604^*$	$0.31 \pm 0.04719^*$
400mg	$2.88 \pm 0.04461^*$	$0.82 \pm 0.05354^*$	$0 \pm 0^*$
Dexamethasone	$2.56 \pm 0.04792^*$	$0.61 \pm 0.04604^*$	$0 \pm 0^*$

* = Results significantly different from Control group, $P < 0.001$

Figure 1. Graphical analysis of excision model using plant extract and dexamethasone on day 7

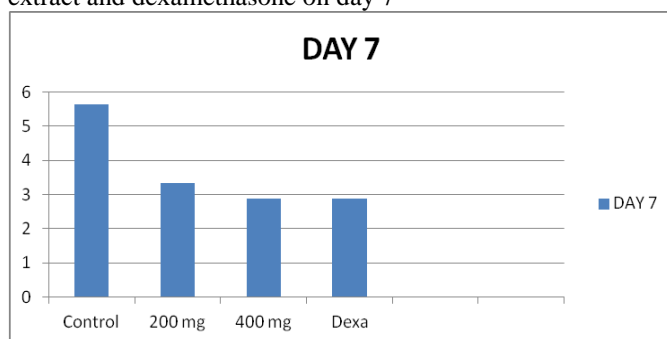


Figure 2. Wound healing area on excision method using plant extract and dexamethasone on day 15

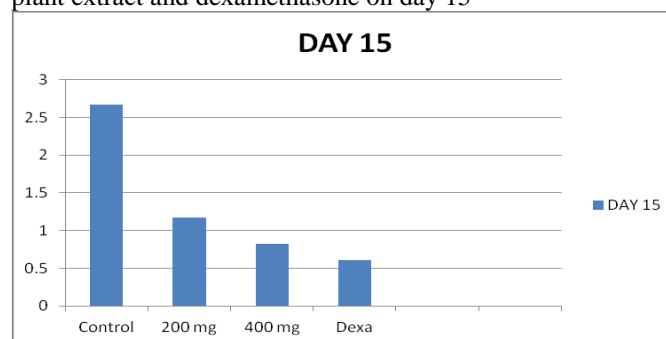


Figure 3. Wound healing area on excision method using plant extract and dexamethasone on day 21

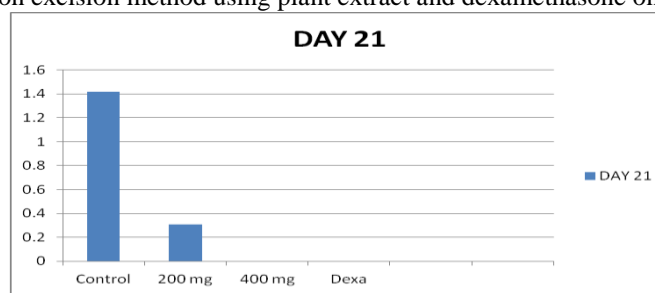
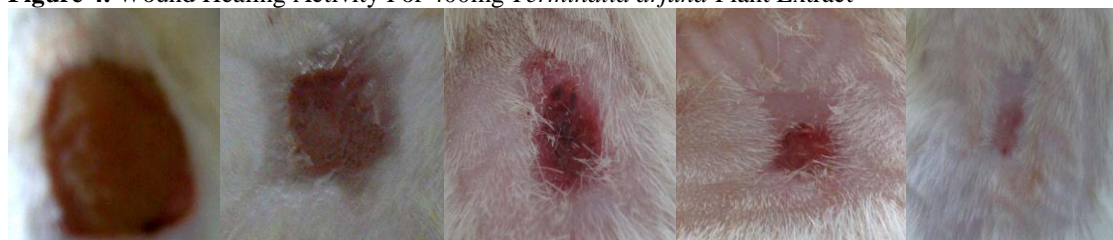

Figure 4. Wound Healing Activity For 400mg *Terminalia arjuna* Plant Extract



DAY 0

DAY 5

DAY 10

DAY 15

DAY 20

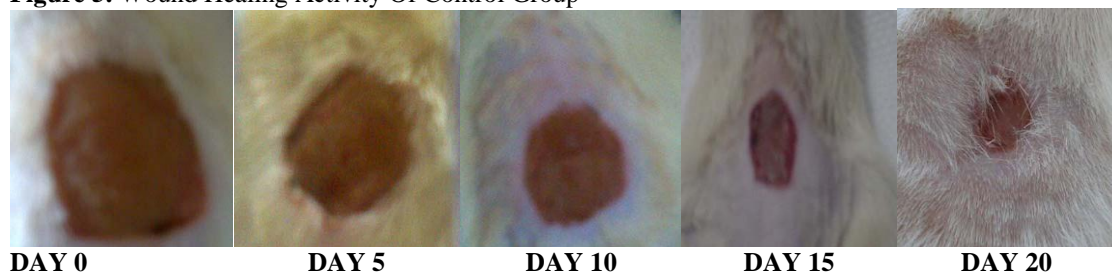
Figure 5. Wound Healing Activity Of Control Group**HISTOPATHOLOGICAL TEST**

FIGURE 6. Van Gieson stained sections of granulation tissue in *Terminalia arjuna* 400mg extract treated group shows less collagen bundles

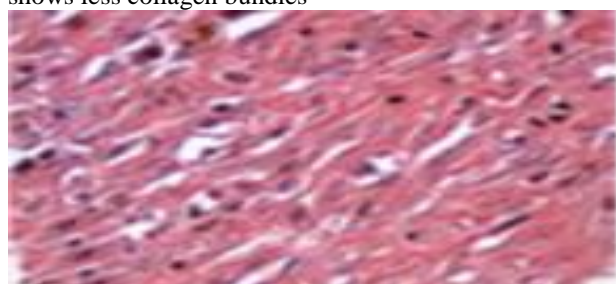


FIGURE 7. Van Gieson stained sections of granulation tissue in control group shows more collagen bundles

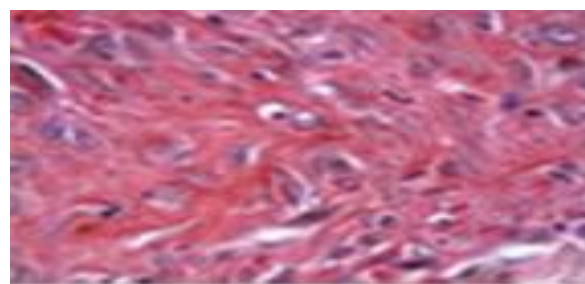
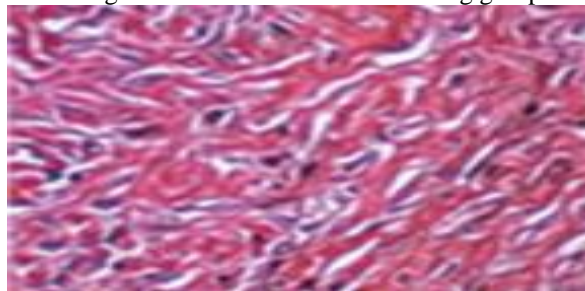


FIGURE 8. Van Gieson stained sections of granulation tissue in standard drug group shows the least collagen bundles

**DISCUSSION**

This study was undertaken to evaluate the wound healing activity of ethanolic extract of *T. arjuna* on excision wounds in male albino wistar rats. In addition, this study was also to compare the activity of healing activity of ethanolic extract of *T. arjuna* against standard drug dexamethasone. The LD₅₀ of *T. arjuna* was found to be safe up to 2000 mg/kg. Thus, it would be safe to use this extract (*T. arjuna*) as a wound healing agent. The significant ($P < 0.001$) shows decrease in wound size on day 21 compared to day 0 for standard drug, dexamethasone and *Terminalia arjuna* 400mg treated rat confirmed the good wound healing activity of *Terminalia arjuna* in the group of rats as shown in Table 4.1. Group of rats which was treated with ethanolic extract of *Terminalia arjuna* at dose level of 200 mg/kg showed significant ($P < 0.001$) different from control group, which proves at this dose, the extract has wound healing activity

but not sufficient as the value appeared to be 1.17 ± 0.046 on day 15th, 0.31 ± 0.047 on 21st day.

Groups of rats pre-treated with ethanolic extract of *Terminalia arjuna* at dose level of 400 mg/kg showed more significant ($P < 0.001$) different from ethanol control group proved by improvement in levels of the wound size 2.88 ± 0.045 on day 7, 0.82 ± 0.054 on day 15 and 0 ± 0 on 21st day. The animals pre-treated with the dexamethasone (1mg/kg) showed high significant ($P < 0.001$) similar to animals treated with 400mg *Terminalia arjuna* reduction in wound size 2.56 ± 0.048 , 0.61 ± 0.046 , 0 ± 0 for day 7, 15 and 21st respectively.

The ethanolic extract of *Terminalia arjuna* used in the study conserved the wound healing activity compared to the control group rats. The ethanolic extract of *Terminalia arjuna* at dose level 400 mg/kg showed prominent wound healing in comparison to the control group and dexamethasone pre-treated group rats.

CONCLUSION

The study is based on wound healing of excision wound on animal model. Through this study, the effectiveness of standard drug, Dexamethasone and *Terminalia arjuna* plant extract can be evaluated. The study is done for 21 days due to full granulation process of wound. The plant extract and standard were given with normal saline as a vehicle. The healing of the wound was evaluated based on planimetric margin. The study proved tested plant extract produced significant therapeutic response against modern medicines that are available in market.

The wound healing property of *Terminalia arjuna* tree bark extract emerge to be due to the existence of its active principle, tannin which hasten the wound healing course. From the results attained in present investigation, it is feasible to conclude that the tree bark extract of *Terminalia arjuna* has significant wound healing activity at the doses tested on excision wound model in animal study. However, further studies should be done to prove the potential of *Terminalia arjuna* in wound healing using other wound models such as incision and dead space wound.

REFERENCES

- Alam Morshed M, Anwarul Haque, Begum Rokeya, Liaquat Ali. Anti-hyperglycemic and lipid lowering effect of *Terminalia arjuna* Bark extract on Streptozotocin induced Type-2 Diabetic Model Rats. *International Journal of Pharmacy and Pharmaceutical Sciences*. 3(2), 2011, 55-66.
- Bairy KL, Rao CM. Wound healing profile of Gingko biloba. *J. Nat. Remed.* 1, 2001, 25-27.
- Duarte IDG, Nakamura M, Ferreira SH. Participation of the sympathetic system in acetic acid-induced writhing in mice. *Brazilian Journal of Medicine and Biological Research*. 21, 1988, 341-343.
- Escárcega RO, Fuentes-Alexandro S, García-Carrasco M, Gatica A, et al. The transcription factor kappa B and cancer. *Clinical Oncology*. 19, 2007, 154-61.
- Gupta R, Singhal S, Goyal A, Sharma VN. Antioxidant and hypocholesterolemic effects of *Terminalia arjuna* tree bark powder: A randomised placebo controlled trial. *Journal Assoc Physician India*. 49, 2001, 231.
- Mahuya S, Gauri DS, Biswajit C. Hepatoprotective and immunomodulatory properties of aqueous extract of *Curcuma longa* in carbon tetra chloride intoxicated Swiss albino mice. *Asian Pacific Journal of Tropical Biomedicine*. 2011, 193-199.
- Moulisha Biswas, Kaushik Biswas, Tarun K Karan, Sanjib Bhattacharya, et al. Evaluation of analgesic and anti-inflammatory activities of *Terminalia arjuna* leaf. *Journal of Phytology*. 3(1), 2011, 33-38.
- Narasimhanaidu Kamalakkannan, Rajagopalan Rukkumani, Penumathsa Suresh Varma, et al. Comparative Effects of Curcumin and an analogue of Curcumin in Carbon Tetrachloride induced Hepatotoxicity in Rats. *Basic and Clinical Pharmacology and Toxicology*. 97, 2005, 15-21.