



EVALUATION OF ANTIULCEROGENIC ACTIVITY OF ETHANOLIC EXTRACT OF STEM BARK OF *Ficus talboti* IN EXPERIMENTAL RATS

Gummalla Pitchaiah^{1*}, Sravani Kandimalla¹, Keerthi TL¹

¹Department of Pharmacology, Hindu College of Pharmacy, Amaravathi Road, Guntur, Andhra Pradesh, India- 522 002.

ABSTRACT

The present study is designed to investigate the antiulcerogenic potential of ethanolic extract of stem bark of *Ficus talboti* (EEFT) against pylorus ligation, ethanol and indomethacin induced ulcer models. The ethanolic extract of *Ficus talboti* stem bark was given by oral route at dose levels of 100 mg/kg and 200 mg/kg body weight. Oral administration of *Ficus talboti* significantly reduced ulcer index in all three models. In addition, EEFT significantly reduced gastric juice volume, free and total acidity but raised the pH of gastric juice as compared to control in pylorus ligated ulcer model. These results confirmed and concluded that ethanolic extract of stem bark of *Ficus talboti* possess antiulcerogenic activity.

Key words: *Ficus talboti*, Ethanolic, Antiulcerogenic, Ulcer Index.

INTRODUCTION

“Peptic ulcer disease” refers to breaks in the mucosa at the stomach and small intestine, principally the proximal duodenum, which is believed to be due to an imbalance between aggressive (acid and pepsin) and protective factors (mucus and bicarbonate). Ulcers have been recognized as one of the most important problem worldwide due to high recurrence and mortality rates especially in complicated cases (Ojewole *et al.*, 2004; Del Valle *et al.*, 2003). Reduction of gastric acid production as well as re-improvement of gastric mucosal production has been the major approaches for therapy of peptic ulcer disease. As a result, drugs of both herbal and synthetic origin are coming up offering newer and better options for treatment of peptic ulcer. Synthetic drugs vary from being proton-pump inhibitors to H₂ antagonist or a cytoprotective agent. At the same time, each of these synthetic drugs confers simpler to several side effects like arrhythmias, impotence, gynaecomastia, hyperplasia and haemopoetic changes (Elango *et al.*, 2012). This has been the major stimulus for the development of new antiulcer

drugs that offer better protection and decreased relapse. Herbal medicine is fast emerging as an alternative treatment to available synthetic drugs for the treatment of ulcer possibly due to lower costs, availability, fewer adverse effects and perceived effectiveness.

Ficus talboti King one of such medicinal plant belongs to the family Moraceae. It is a wild, infrequent and an endemic to India. It is a large evergreen tree without aerial roots. The ethnobotanical views on *Ficus talboti* suggest that aerial parts were used in herbal based drugs in India (Pullaiah, 2006). Studies also showed fruits have high potential of antioxidant activity and nutritional capacity. *Ficus talboti* bark possesses good in-vitro antioxidant and anti-inflammatory activity and used for various purposes such as an astringent medicine, cooling agent, haemostatic, laxative, in improving complexion, in cleaning vagina (Arunachalam *et al.*, 2012). It is also widely used in the treatment of skin diseases, ulcer and soreness in the mouth. Bark powder is useful in curing venereal diseases, diarrhoea, haemorrhages and leprosy (Nadkarni, 1954; Khare, 2007). Hence, the present work is carried out to evaluate the anti-ulcerogenic effect of ethanolic extract of stem bark of *Ficus tallboti* in adult wistar rats using pylorus ligation, ethanol and indomethacin induced gastric ulcer models.

Corresponding Author

Gummalla Pitchaiah

Email: drgummalla@gmail.com

MATERIAL AND METHODS

Plant material

The bark of *Ficus talboti* was collected in the month of October and was taxonomically identified and authenticated by Prof. K.Madhava chetty, Research Officer-Botany, Sri Venkateswara University, Tirupathi. A voucher specimen (No: 1150) was made and deposited at the herbarium.

Preparation of ethanolic extract

The stem bark was shade dried and pulverized in grinder-mixer to obtain a coarse powder. Weighted quantity (100 g) of powder was extracted by ethanolic extraction by soaking in 1L of 90% ethanol for 72 hours at ambient temperature. The mixtures were then filtered and concentrated under reduced pressure in vacuum at 30°C using a rotary evaporator which was stored at -4°C until required for use. Aliquot portions of the crude extract residue were weighed and dissolved in distilled water for use on each day of the experiment (Kokate, 1991).

Preliminary Phytochemical investigation

Phytochemical tests were carried out to find out the presence of phytoconstituents viz flavonoids, saponins, terpenoids, carbohydrates, tannins etc.

Experimental Animals

Wistar albino rats weighing 180-200g were used for the study. All the animals were maintained under standard husbandry conditions at temperature 23±2°C, relative humidity 55±10% and 12 hours light/dark cycle. Animals were fed with standard rodent pellet food and water *adlibitum*. All the experiments were strictly complied with the approval of institutional animal ethics committee.

Acute oral toxicity study

Acute oral toxicity of EEFT was performed according to OECD Guideline 423 (Ecobichon, 1997). Two groups of each were used for the study. Group I served as control and received distilled water. Group II received single oral dose of EEFT (2000 mg/kg). The animals were observed for gross behavioral, neurological, autonomic and toxic effects at short intervals of time for 24 h and then daily for 14 days. Food consumption was monitored daily and body weights were recorded weekly.

Antiulcerogenic activity

Pylorus ligation induced gastric ulcer

Male Wistar rats were divided into four groups, each consisting of six rats. Animals were fasted for 24 h before the study, but had free access to water. Group I received distilled water. Group II received Omeprazole (20 mg/kg) by oral route; Group III & IV received ethanolic extract of *Ficus talboti* at doses of

100mg/kg and 200 mg/Kg body weight by oral route for 14 days prior to pyloric ligation (Shay *et al.*, 1947). Four hours after pylorus ligation, rats were sacrificed and stomach was isolated, gastric contents were collected and centrifuged for 1000 rpm for 10 minutes and the volume of gastric juice measured. The total severity of the ulcers was determined by recording the severity of each ulcer.

Determination of pH

An aliquot of 1ml gastric juice was diluted with 1ml of distilled water and pH of the solution was measured using pH meter.

Determination of total acidity

An aliquot of 1ml gastric juice diluted with 1ml of distilled water was taken into a 50 ml conical flask and two drops of phenolphthalein indicator was added to it and titrated with 0.01N NaOH until a permanent pink color was observed. The volume of 0.01N NaOH consumed was noted. The total acidity is expressed as mEq/L by the following formula:

Acidity =

$$\frac{\text{Vol. of NaOH} \times \text{Normality of NaOH} \times 100 \text{ mEq/L}}{0.1}$$

Determination of free acidity

Instead of phenolphthalein indicator, the Topfer's reagent was used. Aliquot of gastric juice was titrated with 0.01N NaOH until canary yellow colour was observed. The volume of 0.01N NaOH consumed was noted. The free acidity was calculated by the same formula for the determination of total acidity.

Ethanol-induced gastric ulcer

All the animals were fasted 24 hours before administration of ethanol. The animals were divided into four groups each consisting of six rats. Group I represented control which received distilled water, Group II treated with Omeprazole (20 mg/kg p.o.) administered 30min prior to induction of gastric ulcer and Group III&IV received ethanolic extract of *Ficus talboti* at doses of 100 mg/kg & 200mg/kg respectively for 14 days. After 24 hours of last dose, Gastric ulcers were induced with absolute ethanol 90% (1ml/200g) orally (De Pasquale *et al.*, 1995). They were kept in specially constructed cage to prevent coprophagia during and after the experiment. The animals were anaesthetized 1 hour later with anaesthetic ether and stomach was incised along the greater curvature and ulceration will be scored (Malarajan *et al.*, 2007).

Indomethacin-induced gastric ulcer

All the animals were fasted 24 hours before administration of indomethacin. The animals were divided into four groups each consisting of six rats. Group I served as control group which received distilled water.

Group II received standard drug Omeprazole (20mg/kg p.o.). Group III & IV, pretreated with EEFT at dose levels of 100 mg/kg & 200 mg/kg by oral route prior to indomethacin administration (Guidobono *et al.*, 1997). The animals were sacrificed by cervical dislocation 6 h later. The stomachs were harvested, opened along the greater curvature and the mucosa was exposed for macroscopic evaluation. The ulcerated area was assessed and the ulcer index (UI) was calculated.

Macroscopic evaluation of stomach

The stomachs were opened along the greater curvature, rinsed with saline to remove gastric contents and blood clots and examined by a 10X magnifier lens to assess the formation of ulcers. The numbers of ulcers were counted. Scoring of ulcer will be made as follows:

- (0): No ulcer
- (1): Superficial ulcers
- (2): Deep Ulcers
- (3): Perforation

Mean ulcer score for each animal will be expressed as ulcer index. The percentage of ulcer protection was determined as follows:

Ulcer index (UI) was measured by using following formula: $UI = UN + US + UP \times 10^{-1}$

Where,

UI= Ulcer Index; UN = Average number of ulcers per animal; US = Average number of severity score; UP = Percentage of animals with ulcers

Percentage inhibition of ulceration was calculated as below:

% Inhibition of Ulceration =

$$\frac{(\text{Ulcer index}_{\text{Control}} - \text{Ulcer index}_{\text{Test}}) \times 100}{\text{Ulcer index}_{\text{Control}}}$$

Histopathological Examination

For histopathological examination, the stomach was washed thoroughly with saline, dehydrated in gradual ethanol (50-100%), cleared in xylene and finally embedded in paraffin. Sections (size of 4-5 mm) were prepared and stained with hematoxylin and eosin (H-E) dye for microscopic observation (magnification 100x).

Statistical analysis

The values Mean \pm SEM are calculated for each parameter. For determining the significant inter group difference each parameter was analysed separately and one-way analysis of variance was carried out and the individual comparisons of the group mean values were done using Dunnett's test.

RESULTS

Preliminary phytochemical screening

The preliminary phytochemical screening showed the presence of different phytoconstituents groups such as carbohydrates, saponins, flavonoids, terpenoids and tannins.

Acute oral toxicity

Animals did not show any signs of toxicity during the observation period (14 days). The ethanolic extract administered safely up to a maximum dose 2000 mg/kg b.w.

Antiulcerogenic activity

Pylorus ligation induced ulcer model

In pylorus ligation induced ulcer model, pretreatment with EEFT in two different doses showed significant reduction in ulcer index, gastric volume, free acidity, and total acidity as compared to the control group. It was also showing protection index of 49.25 % and 67.72% at the dose of 100 and 200 mg/kg respectively in comparison to control, whereas Omeprazole as reference standard drug was reduction of ulcer 86.15% and the results are tabulated in Table-1.

Ethanol induced ulcer model

In ethanol induced model, pretreatment of rats with *Ficus talboti* ethanolic extract produced significant protection from ethanol induced ulceration as compared to control rats. The protection was significantly reduced the severity of ulcer and caused a significant reduction of ulcer index by 31.57% and 58.54% at 100 and 200 mg/kg dose levels respectively. Omeprazole produced more significant gastric ulcer protection as compared to control group (Table 2).

Indomethacin induced ulcer model

In this model, pretreatment of rats with *Ficus talboti* ethanolic extract produced significant protection from indomethacin induced ulceration as compared to control rats. The protection was significantly reduced the severity of ulcer and caused a significant reduction of ulcer index by 28.57% and 59.21% as compared to control. Further, omeprazole produced more significant gastric ulcer protection (Table 2).

Histopathological Examination

In experimental control group, gastric mucosa showed many pit-shaped ulcers, mucosal and submucosal congestion, along with surface erosion at several places. In omeprazole treated group, gastric mucosa revealed mild superficial erosions with intact submucosa and deeper mucosa. In EEFT groups, superficial erosions and a few ulcers with mild disorganization of mucosa were observed.

Table 1. Effect of ethanolic extract of *Ficus talbotii* Pylorus ligation model in rats

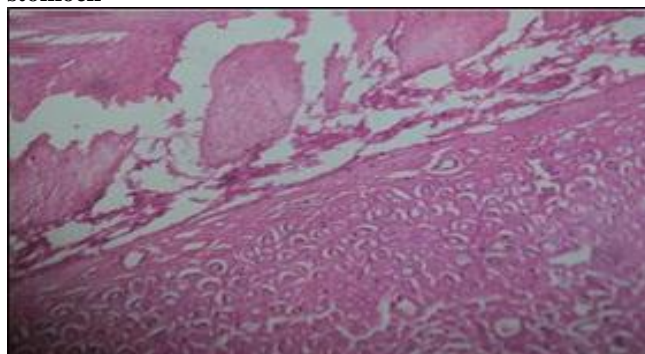
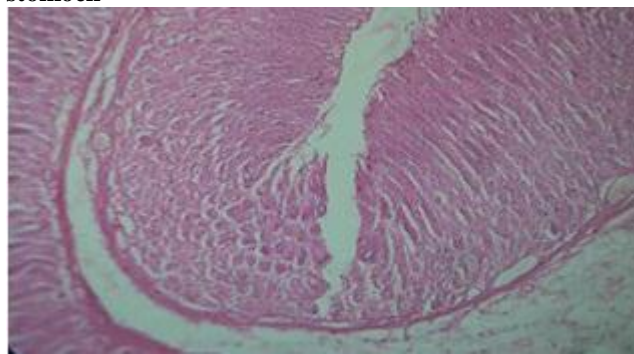
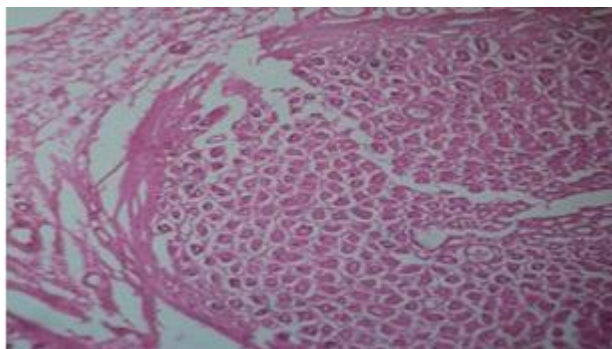
Treatment	Volume of Gastric Content (ml/100g)	Free acidity (mEq/liter)	Total acidity	Ulcer index	% of Ulcer Protection	P ^H of gastric juice
Control	3.16±0.15	32.80±0.15	71.80±3.59	10.69±0.11	--	1.94±0.11
Omeprazole (20mg/kg)	2.14±0.17**	8.00±0.71***	30.20±2.28***	1.48±0.05***	86.15	4.3±0.14***
EEFT (100mg/kg p.o.)	2.70±0.10*	21.20±0.58**	52.00±0.71*	5.42±0.04**	49.25	2.41±0.22**
EEFT (200 mg/kg p.o.)	2.34±0.12**	13.59±1.23***	37.40±2.42**	3.45±0.05***	67.72	2.85±0.02**

Data in each column is represented as Mean ± SEM; *indicates p<0.05, ** indicates p<0.01 and ***indicates p< 0.001 when compared to the control group.

Table 2. Effect of different doses of *Ficus talbotii* against ethanol and indomethacin induced gastric ulcer in rats

Treatment	Ethanol		Indomethacin	
	Ulcer index	% of ulcer protection	Ulcer index	% of ulcer protection
Control	12.83 ± 0.21	---	11.14 ± 0.36	---
Omeprazole (20 mg/kg)	4.53 ± 0.21***	74.34	4.56 ± 0.25***	71.42
EEFT (100 mg/kg, p.o.)	8.66 ± 0.50**	31.57	7.54 ± 0.57**	28.57
EEFT (200 mg/kg, p.o.)	6.32 ± 0.31***	58.54	5.66 ± 0.50***	59.21

Data in each column is represented as Mean ± SEM; *indicates p<0.05, ** indicates p<0.01 and ***indicates p< 0.001 when compared to the control group.

Fig 1. Stomach of control rat showing severe erosions and disorganization from normal architecture of the stomach**Fig 2. Stomach of rat treated with omeprazole showing less erosions restoring the normal architecture of the stomach****Fig 3. Stomach of rat treated with EEFT showing few erosions with mild disorganization from normal architecture of the stomach**

DISCUSSION

The antiulcerogenic activity of the bark of *Ficus talbotii* was evaluated by employing pylorus ligation, ethanol and indomethacin induced ulcer models. These models represent some of the most common causes of gastric ulcer in humans (Patil *et al.*, 2009). Gastric ulcers by pyloric ligation are due to stress induced increase in

gastric hydrochloric acid secretion and/or stasis of acid and the volume of secretion is also an important factor in the formation of ulcer due to exposure of the unprotected lumen of the stomach to the accumulating acid leading to auto digestion of the gastric mucosa and breakdown of the gastric mucosal barrier (Prasad *et al.*, 2014). Treatment with *Ficus talbotii* significantly inhibited the formation of

ulcers in the pylorus ligated rats and also decreased both the concentration and volume of acid and increased the pH, it is suggested that *Ficus talboti* can suppress gastric damage by anti-secretory activity.

Ethanol induced gastric lesion formation is multifactorial and is may be stasis in gastric blood flow which contributes to the development of the haemorrhage and necrotic aspects of tissue injury. Alcohol rapidly penetrates in gastric mucosa apparently causing cell and plasma membrane damage leading to increase the intracellular membrane permeability of sodium and water. Ethanol produces necrotic lesions in the gastric mucosa by its direct toxic effect, reducing the secretion of bicarbonates and production of mucus (Szabo *et al.*, 1995; Marhuenda *et al.*, 1993).

Indomethacin is a cyclooxygenase inhibitor which suppresses gastroduodenal bicarbonate secretion reduces endogenous prostaglandin biosynthesis and disrupts the mucosal barrier as well as mucosal blood flow in animals. It is also well known that prostaglandin synthesized in large quantities by the gastrointestinal mucosa can prevent experimentally induced ulcers by ulcerogens. Thus when the gastric ulcer is induced by indomethacin, the cytoprotective effect of the anti-ulcer agent can be mediated through endogenous prostaglandins (Brestel 1994). Further, several studies also evidenced that the gastric ulcer is mainly due to damage of gastric mucosa by free radicals and reactive oxygen species (Bandyopadhyay *et al.*, 2002). In both ethanol and indomethacin induced ulcer models, *Ficus talboti* treatment significantly reduced the severity of the ulcers.

Thus, the antiulcerogenic property of *Ficus talboti* in pylorus ligation model is evident from its significant reduction in free acidity, total acidity, number

of ulcers and ulcer index. Further, the antiulcerogenic potential was supported by significant reduction in ulcer index in ethanol and indomethacin induced ulcer models.

The preliminary phytochemical analysis showed the presence of carbohydrates, saponins, flavonoids, terpenoids and tannins. Although the mechanism of ulcer prevention by this extract is not clear, reduction of deleterious effects of free radicals and reactive oxygen species in gastrointestinal lumen by *Ficus talboti* (Arunachalam *et al.*, 2012) by active constituents like flavonoids could be one of the possible mechanisms for its antiulcerogenic potential. Further, the flavonoids were also reported for their antiulcerogenic activity and gastric protection as these compounds would be able to stimulate mucus, bicarbonate and the prostaglandin secretion (Sakat *et al.*, 2009).

CONCLUSION

We have demonstrated in this study that the ethanolic extract of *Ficus talboti* bark has an antiulcerogenic property against experimentally induced ulcers in rats and this study confirms folkloric claims of the benefits of *Ficus talboti* in treatment of ulcer. The present studies suggest that the antiulcerogenic potential is probably due to the presence of flavonoids and tannins. Further studies are being carried out to characterize and explore the biological activity of the compounds present in the extract.

ACKNOWLEDGMENTS

Authors are sincerely thanking the Management, Principal and Animal ethical committee, Hindu College of Pharmacy for their support during the study.

REFERENCES

- Antwi S, Martey ON, Donkor K, Nii-Ayitey Okine LK. Anti-diarrhoeal activity of *Blighia sapida* (Sapindaceae) in rats and mice. *J Pharmacol Toxicol*, 4, 2009, 117-125.
- Arunachalam K, Parimelazhgan T. Free radical scavenging, anti-inflammatory activity and phytochemical constituents of *Ficus talboti* King bark. *Free Radical Biol Med*, 53, 2012, S107- S108.
- Bandyopadhyay D, Biswas K, Bhattacharyya M, Reiter RJ, Banerjee RK. *Indian J Exp Biol*, 40, 2002, 693-705.
- Brestel EP, Dyke KV. Lipid mediators of homeostasis and inflammation. In: Modern Pharmacology, 4th ed. *Library Campus Cataloguing*, 1994, 477-487.
- De Pasquale R, German MP, Keita A, Sanogo R, Iauk L. Antiulcer activity of *Pteleopsis suberosa*. *J Ethnopharmacol.*, 47, 1995, 55-58.
- Del Valle J, Chey W, Scheiman J. Acid Peptic Disorders. In: T. Yamada, D. Aplers, N. Kaplowitz (Eds.) Textbook of Gastroenterology. 4th ed. Philadelphia: Lippincott Williams and Wilkins, 2003, 1321-1376.
- Ecobichon DJ. The basis of toxicity testing. CRS Press, New York, 1997, 43-49.
- Elango V, Carolin Oliver, Raghu PS. Antiulcer activity of the Leaf ethanolic extract of *Mimosa pudica* in Rats. *Hygeia J D Med*, 4 (1), 2012, 34-40.
- Guidobono F, Pagani F, Ticozzi C, Sibilina V, Pecile A, Netti C. Protection by amylin of gastric erosions induced by indomethacin or ethanol in rats. *Br J Pharmacol*, 120, 1997, 581-586.
- Kaur Amandeep, Singh Robin, Sharma Ramica, Kumar Sunil. Peptic ulcer: a review on etiology and pathogenesis. *IRJP*, 3(6), 2012, 34-38.
- Khare CP. Indian medicinal plants. An illustrated dictionary. New Delhi, Springer, 2007, 269.

- Kokate CK. Practical Pharmacognosy. Nirali Prakasham, Pune, 1991.
- Malarajan, P, Gopalakrishnam G, Narasimhan S, Vehi KJ, Karimani S. Antiulcer activity of crude alcoholic extract of *Toona ciliata* Roemer (heart wood). *J Ethnopharmacol*, 110, 2007, 348-351.
- Marhuenda E, Martin MJ, Alarcon de la Lastra C. Antiulcerogenic activity of aescine in different experimental models. *Phytotherapy Research*, 7, 1993, 13-16.
- Nadkarni AK. Nadkarni's Indian materia medica, 1319, 1954, 968.
- Neelam Balekar, Dinesh Kumar Jain, Hitesh Jawanjal. Evaluation of antiulcer activity of bark extract of *Albizzia lebeck* linn. *South Pacific Journal of Pharma and Bio Science*, 1, 2013, 043-050.
- Ojewole EB. Peptic Ulcer Disease. In: C.N. Aguwa (Ed.) Therapeutic Basis of Clinical Pharmacy in the Tropics. 3rd ed. Enugu: SNAAP Press, 2004, 541-564.
- Patil P, Prakash T, Shivakumar H, Pal S. Anti-ulcer and anti-secretory properties of the *Butea monosperma* (Lam) Bark extract with relation to antioxidant studies. *Iran J Pharmaco Therap*, 8, 2009, 1-6.
- Prasad K, Nagaraju B, Ramesh A, Naresh P, Vinay Kumar I, Naresh D. Evaluation of antiulcer and in-vitro antioxidant activity of methanolic extract of *Psidium guajava* root in albino wistar rats. *Int J Phytopharmacol*, 5(1), 2014, 59-67.
- Pullaiah T, Chandrasekhar Naidu K. Antidiabetic plants in India and herbal based antidiabetic research. *Regency publications, New Delhi*, 2006, 184-185.
- Sakat SS, Juvekar RA. Antiulcer Activity of Methanol Extract of *Erythrina indica* Lam. Leaves in Experimental Animals. *Pharmacognosy Res*, 1, 2009, 396-401.
- Shay H, Komarov SA, Fels SS, Meranze D, Grunstein M, Sipler H. A Simple method for uniform production of gastric ulcers in rats. *Gastroenterol*, 5, 1945, 43-61.
- Szabo S, Kusstatscher S, Sakoulas G, Sandor Z, Vincze A, Jadus M. 'Growth factors: New "endogenous drug" for ulcer healing', Scandinavian. *J Gastroenterol*, 210, 1995, 15-18.