



WOUND HEALING ACTIVITY OF *GRACILARIA EDULIS* (GMELIN) HYDRO ALCOHOLIC EXTRACT USING EXCISION AND DEAD CELL WOUND MODEL IN WISTAR RATS

Pranabesh Sikdar^{1*} and M. Venkata Ramana²

¹Department of Pharmaceutical Chemistry, Seven Hills College of Pharmacy, Tirupati-517561, Andhra Pradesh, India.

²Gurram Balanarasaiah Institute of Pharmacy, Edulabad (v), Ghatkesar (M), Ranga Reddy– 501 301, Andhra Pradesh, India.

ABSTRACT

Recently a lot of attentions have been drawn by the marine algae because it contain different bioactive compounds which are useful in the medicinal field. *Gracilaria edulis* (Gmelin) Linn belonging to family *Rhodophytaceae* various disease like cancer, acquired immune-deficiency syndrome (AIDS), inflammation, pain, arthritis, as well as viral, bacterial, and fungal infections. Their fore purpose of present study was to evaluate wound healing activity of *Gracilaria edulis* (Gmelin) extract against excision and dead space wound model on wistar rats. Both concentrations of hydro-alcoholic extracts showed significant response in both the wound type tested when compared with control group They were compared with vitamin E in the dead cell wound method and nitrofurazone in excision method. In both the model the HAE have shown significant activity compared to the standard. The excision methods have shown 92.12% at 200mg/kg and 97.89% at 400mg/kg concentrations. While the dead cell wound model have shown 63.83±0.7032 and 36.17±0.8333as wet weight and dry weight respectively at 200mg/kg and 41.67±0.6667 and 24.17±0.9458 weight of wet and dry weight respectively.

Key words: Wound healing, *Gracilaria edulis* (Gmelin), Hydroalcoholic extract (HAE), Nitrofurazone.

INTRODUCTION

Wound healing involves various steps like coagulation, formation of granulation tissue, coagulation and acquisition of wound strength. During the formation of new tissue endothelial cell proliferates¹ and forms new blood vessel (Morton JJP and Malone MH, 1972). The healing process in full skin wound includes coagulation, inflammation, tissue formation and tissue remodelling. Initially the skin wounds are filled with blood and a fibrin clot. The fibrin clot acts as the first protection against the infection other than hemostatis. Here in this work we have planned to carry out the wound healing activity with this particular species. The role of the neutrophils is to protect the wound from any type of contamination during the inflammation. The macrophages remove the wound debris

and help to form new dermal matrix. Secondary metabolites like alkaloids, phenolics, steroids, terpenoids have been characterized from mangroves and have toxicological, pharmacological and ecological significance (Bandaranayake WM, 2002; Kokpal V *et al.*, 1990).

Gracilaria edulis belonging to family *Rhodophytaceae* found in various region of India, Srilanka and Southeast asia (Anonymous 1). They are used to treat diseases like Cancer, Acquired Immune-Deficiency Syndrome (AIDS), inflammation, pain, arthritis, as well as viral, bacterial and fungal infections (Cynthia Layse *et al.*, 2011). The literature survey revealed that no scientific study on wound healing activity of hydroalcoholic extract of this plant has been reported. Their fore purpose of present study was to evaluate wound healing activity of *Gracilaria edulis* (Gmelin) extract against excision and incision wound model in wistar rats.

Corresponding Author

Pranabesh Sikdar

Email: pranawesh@rediffmail.com

MATERIALS AND METHOD

Plant material

Gracilaria edulis (Gmelin) were collected from tuticorin island of Tamil Nadu, India.

Extraction of plant material

The algae were shade dried and were coarse powdered. About 400 gm of dry powder was taken in a Stoppered conical flask and it was defatted with Petroleum ether. The defatting was continued for 3-4 days with occasional shaking. The Petroleum ether extract was filtered. The marc left after defatting was taken out and dried under shade to get a dry mass, then extracted with ethanol and water (hydroalcoholic) by using cold maceration extraction. The extraction was continued for 6-8 days with occasional shaking. The hydroalcoholic extract was filtered, concentrated under reduced pressure to a semisolid mass and was made free from solvent. The final obtained extract was weighed; percentage yield was calculated and stored in a cool place.

Animals

Wister albino rats weighing between 180-230gm each were used for this experiment. The animals were maintained in a well-ventilated room with at 12:12 h light, dark cycle in polypropylene cages and maintained at 22±1°C with humidity at 55±5%. They were fed balanced rodent pellet diet and tap water *ad libitum* throughout the experimental period. Ethical committee clearance was obtained from IAEC (Institutional Animal Ethics Committee) of CPCSEA.

ACUTE ORAL TOXICITY STUDIES

Experimental Procedure

The HAE was selected for acute oral toxicity study. The starting dose level of HAE was 2000mg/kg, p.o. to albino wistar rats. As most of the crude extracts possess LD₅₀ value more than 2000 mg/kg, p.o. Dose volume was administered 0.2ml per 100gm body weight to overnight fasted rats. Food was withheld for a further 3 to 4h after administration of HAE observed for signs of toxicity. The body weight of the rats before and after administration were noted, the changes in skin and fur, eyes, mucous membranes, respiratory, circulatory, autonomic and central nervous system, motor activity and behavior pattern were observed. The signs of tremors, convulsions, salivation, diarrhea, lethargy, sleep and coma, as well as the onset of toxicity and signs of toxicity were also noted (Nayak SB *et al.*, 2009; OCED, 2002). The results are given in table 1.

WOUND HEALING ACTIVITY

The wound healing activity was examined in ether anesthetized rats in two different wound model.

Dead Space Wound Model

In dead space wound model the animals were divided into four groups each group contain six rats. Rats are anaesthetized by using diethyl ether. Dead space wound were inflicted by implanting sterile cotton pellets (5 mg each), one on either side of the groin and axils on ventral surface of each rat. The following treatment was continued for 10 days after post wounding day.

Experimental design

Group I- Received vehicle (Negative control) 1% w/v SCMC, 1ml/100 g

Group II - Received HAE (200mg/kg body weight p.o) suspended in 1% w/v SCMC

Group III - Received HAE (400mg/kg body weight p.o) suspended in 1% w/v SCMC

Group IV – Received standard drug (Diclofenac sodium, 100mg/kg) p.o. respectively for 10 days.

All animals were sacrificed by cervical dislocation on the 10th post wounding day and cotton pellets were surgically dissected out. The isolated cotton pellets were separated from extraneous tissue and dried at 60°C until weight become constant. The net dry weight of each cotton pellet was determined (after subtracting the initial weight of the cotton pellet). The mean weights of the cotton pellet of the control and treatment groups were calculated. The percentage of wound healing activity was calculated by inhibition of increase in the weight of the cotton pellet was estimated (Nayak *et al.*, 2009).

The percent inhibition increase in the weight of the cotton pellets was calculated by:

$$\% \text{ Inhibition} = [W_c - W_t / W_c] \times 100$$

W_c = Pellet weight of the control group

W_t = Pellet weight of the drug treated group

Excision wound model

For the excision wound studies, twenty four healthy wister rats (150- 200 gm) was taken, divided in four groups of six each. Rats depilated by removing hair at the dorsal thoracic region before wounding and anaesthetized by diethyl ether. The area of wound 500mm² was made (1 cm away from the vertebral column 5 cm away from the ear) on the dorsal interscapular region of each animal by excising the skin with surgical scissors, under aseptic conditions. Haemostasis was achieved by using wound with swab soaked in normal saline.

The animals of group-I served as control and were applied with vaseline, group-II and Group-III were treated with HAE (200 and 400 mg/kg respectively) were applied with vaseline once daily until complete healing. Group-IV treated with Nitrofurazone ointment (0.2% w/w) obtained from Smith Kline– Beecham Pharmaceuticals Bangalore, India, was used as standard

drug for comparing the wound healing potential of the extract.

The wounds were traced on mm² graph paper on the days of 4th, 8th, 12th and 16th. The wound closure was measured at regular intervals of time to see the percentage of wound closure and epithelization time that indicates the formation of new epithelial tissue to cover the wound. The number of days required for falling of the scar without any residual of the raw wound gave the period of Epithelization (Mortan JJP and Malone, 1972.).

Wound closure % = Wound area on day 0 - Wound area on day n / Wound area on day 0 x 100 where n = number of days 4th, 8th, 12th, and 16th day.

Statistical analysis

The data were expressed as mean \pm standard error mean (S.E.M). The Significance of differences among the group was assessed using one way and multiple way analysis of variance (ANOVA). The test followed by Dunnett's test p values less than 0.05 were considered as significance.

RESULTS AND DISCUSSION

In dead space wound model, HAE at the dose of 200 and 400mg/kg showed significantly decreased in wet

and dry weight of granulation tissue (63.83 \pm 0.7032 & 41.67 \pm 0.6667) and (36.17 \pm 0.8333 & 24.17 \pm 0.9458) respectively as compare to control group (104.17 \pm 2.915 and 65.50 \pm 1.258). The standard drug (36.17 \pm 0.9098 and 19.83 \pm 0.6009) showed significantly decreased in wet and dry weight of granulation tissue compared to HAE at the dose of 200 and 400 mg/kg. Moreover, HAE at the dose of 200 and 400mg/kg significantly reduced its formation of wet weight by 38.73% & 59.99 and dry weight by Histopathology of skin at day 10 stained with H&E (100x). Histopathological characteristics of rat skin on 16th day by treatment. Group I: shows early epithelization and granulation tissue, reduced fibroblast cells, collagen fibers and abundance of mononuclear inflammatory cells in excision wound. Group II & III: Histopathological characteristics of rat skin on 16th day by treatment HAE (200 & 400mg/kg). Figure 2 shows large amount of granulation tissue, increased fibroblast cells, collagen fibers and small number of mononuclear inflammatory cells in excision wound. Group IV: Histopathological characteristics of rat skin on 16th day by treatment with standard Nitrofurazone ointment (0.2% w/w). Figure 2 shows increased fibroblast cells, collagen fibers and healed skin structures with well-formed, near to normal epidermis in excision wound.

Table 1. Effect of topical application of HAE on Excision Wound

Groups	Treatment	Wound area in mm ²					% contraction
		Initial	4 th	8 th	12 th	16 th	
Group-I	Control Vaseline	513.33 \pm 1.764	375.50 \pm 3.030	272.33 \pm 2.951	214.33 \pm 1.606	159.17 \pm 1.352	68.99
Group-II	HAE 200 mg/kg, topical	511.50 \pm 2.547	300.17 \pm 3.038*	185.17 \pm 2.676**	117.50 \pm 2.566**	40.33 \pm 1.202**	92.12
Group-III	HAE 400 mg/kg, topical	514.33 \pm 2.108	222.33 \pm 2.275**	135.67 \pm 1.229**	74.83 \pm 1.956**	10.83 \pm 0.8333**	97.89
Group-IV	(Nitrofurazone ointment (0.2% w/w) topical	518.17 \pm 1.990	210.67 \pm 1.542**	113.83 \pm 1.400**	49.33 \pm 1.453**	7.17 \pm 0.6009**	98.62

Values are expressed as mean \pm SEM of six observations. Statistical significant test for comparison was done by ANOVA, followed by Dunnett's test. Comparison between Group IVs Group II, III& IV. *p<0.05; ** p<0.01.

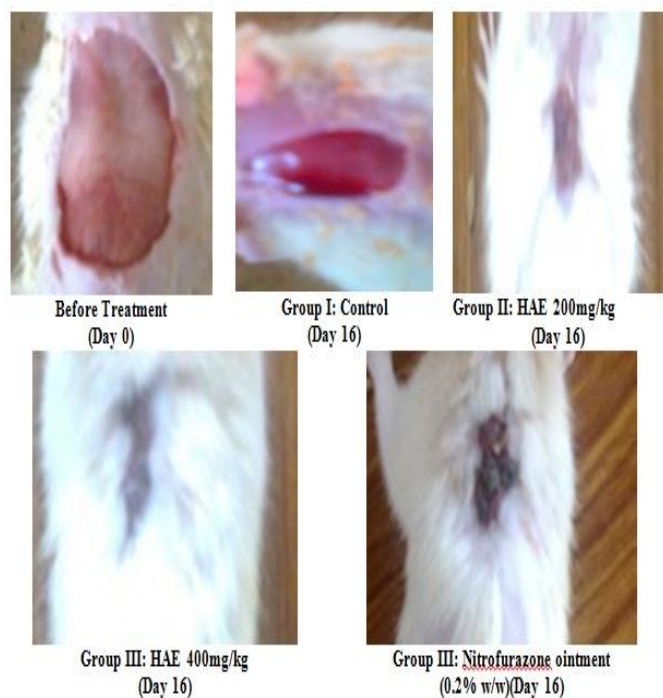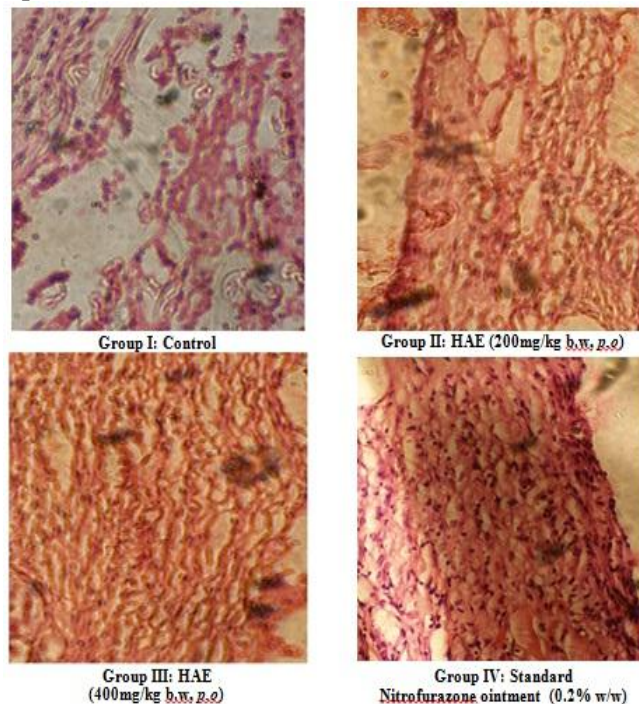
Table 2. Effect of HAE on dead space wound model

Groups	Treatment & Dose	% inhibition	
		For wet weight	For dry weight
I	Control (1% w/v SCMC, 1ml/100g)	-	-
II	HAE (200mg/kg b.w, p.o)	38.73	44.78
III	HAE (400mg/kg b.w, p.o)	59.99	63.10
IV	Vitamin E, 100mg/kg, p.o.	65.28	69.73

Table 3. Percentage inhibition of HAE on dead space wound model

Groups	Treatment & Dose	Weight of Pellets (mg)	
		Wet weight	Dry weight
I	Control (1% w/v SCMC, 1ml/100g)	104.17 \pm 2.915	65.50 \pm 1.258
II	HAE (200mg/kg b.w, p.o)	63.83 \pm 0.7032**	36.17 \pm 0.8333**
III	HAE (400mg/kg b.w, p.o)	41.67 \pm 0.6667**	24.17 \pm 0.9458**
IV	Vitamin E, 100mg/kg, p.o.	36.17 \pm 0.9098**	19.83 \pm 0.6009**

Values are expressed as mean \pm SEM of six observations. Statistical significant test for comparison was done by ANOVA, followed by Dunnett's test. Comparison between Group IVs Group II, III& IV. *p<0.05; ** p<0.01.

Fig 1. Wound healing activity of HAE on Excision wound model**Fig 2. Histopathology studies on excision wound Epithelization in Rats**

SUMMARY AND CONCLUSION

The red algae *G.edulis* was collected from the tuticorin island of tamil nadu. The algae was shade dried and were coarse powdered. The hydro alcoholic extraction was carried out and the extract was concentrated. Later kept in a cool and dried place. The hydro-alcoholic extracted was tested for the wound healing activity by two different method. The excision methos and the dead cell wound model. The two different concentration of the HAE was taken (200mg/ kg and

400mg/kg). They were compared with vitamin E in the dead cell wound method and nitrofurazone in excision method. In both the model the HAE have shown significant activity compared to the standard. The excision method have shown 92.12% at 200mg/kg and 97.89% at 400mg/kg concentrations. While the dead cell wound model have shown 63.83 ± 0.7032 and 36.17 ± 0.8333 as wet weight and dry weight respectively at 200mg/kg and 41.67 ± 0.6667 and 24.17 ± 0.9458 weight of wet and dry weight respectively.

REFERENCES

- Anonymous 1. http://www.algaebase.org/search/species/detail/?species_id=1899.
- Bandaranayake WM. Bioactives, bioactive compounds and chemical constituents of mangrove plants. *Wetland Ecol. Manage*, 10, 2002, 421-452.
- Cynthia Layse F. de Almeida, Heloína de S. Falcão, Gedson R. de M. Lima, Camila de A. Montenegro, Narlize S. Lira, Petrônio F. de Athayde-Filho, Luis C. Rodrigues, Maria de Fátima V. de Souza, José M. Barbosa-Filho, and Leônia M. Batista. Bioactivities from Marine Algae of the *Genus Gracilaria*. *Int J Mol Sci.*, 12(7), 2011, 4550–4573.
- Duke NC. Mangrove floristics and biogeography. In: Robertson AI and Alongi DM (eds) *Tropical Mangrove Ecosystems*. American Geophysical Union, Washington DC. 1992, 63-100.
- Kokpal V, Miles DH, Payne AM, Chittawong V. Chemical constituents and bioactive compounds from mangrove plants. *Stud Nat Prod Chem*, 7, 1990, 175-199.
- Morton JJP and Malone MH. Evaluation of vulnerary activity by an open wound procedure in rats. *Arch int Pharmacodyn Therapeutics*, 196, 1972, 117-126.
- Nayak SB, Sandiford S, Maxacell A, Evaluation of the wound healing activity of ethanolic extract of *Morindacitrifolia* L leaf. *eCAM*, 6, 2009, 351-356.
- OECD. Acute oral toxicity, acute oral toxicity class method guidenlines 423 adopted 20:3, 1996, In: Eleventh addendum to the OECD guidenlines for the testing of chemicals organization for economical co- operation and development paris, 2002.