



ANTIDIABETIC AND HYPOLIPIDEMIC EFFECTS OF *CURCULIGO ORCHIOIDES* IN ALLOXAN INDUCED EXPERIMENTAL DIABETIC RATS

Sarath Chandiran I¹, Anandakirouchenane E^{*2}, Kadalmani B³

¹Principal, Gokula Krishna College of Pharmacy, Sullurpet, Andhra Pradesh, India.

²Research Scholar, Prist University, Vallam, Thanjavur, Tamil Nadu, India.

³Department of Animal Science, Bharathidasan University, Thiruchirapalli, Tamil Nadu, India.

ABSTRACT

Diabetes mellitus is an incapacitating and often serious disease with increasing prevalence in rural populations throughout the world. In the current study, the putative antihyperglycemic and antihypolipidemic effects of *C. orchioides* were evaluated in comparison with those of glyclazide, a standard drug for therapy of diabetes mellitus. Diabetes was induced experimentally in 12-hr fasted rats by intraperitoneal injections of Alloxan (120mg/kg b.w.). Subsequent, to oral administration of *C. orchioides* rhizome (200 mg/kg b.w.) and glibenclamide (10mg/kg.bw/day) to the diabetic rats for 21 days, the following observations were made in comparison with untreated diabetic rats: significantly lower mean levels of fasting blood glucose and glycosylated hemoglobin, significantly elevated serum insulin levels and the extract was also found to have antihypolipidemic activity as evident by significantly ($p < 0.05$) elevated in serum triglycerides, total serum cholesterol, and serum LDL respectively, along with ($p < 0.05$) an increase in serum HDL on *C. orchioides* treated rats. Histopathology of pancreatic tissue section revealed significant protective effect of *C. orchioides* treatment. These results suggest that *C. orchioides* exhibits antihyperglycemic and antihypolipidemic effects in alloxan-induced experimental diabetic rats.

Key words: Alloxan, *Curculigo orchioides*, OGTT, Insulin, Hypoglycemia, Hypolipidaemia.

INTRODUCTION

Diabetes mellitus, a heterogeneous metabolic disorder characterized by chronic hyperglycemia and insulin deficiency or resistance, is caused due to alteration in carbohydrate, lipid, and protein metabolism (Muralik *et al.*, 2003; Rungseesantivanon *et al.*, 2010). Hyperglycemia and hyperlipidemia are major causes of morbidity and mortality of diabetes (Taskinen MR, 2002). This is a major and growing public health problem throughout the world with an estimated worldwide prevalence of 171 million people in 2000, which is expected to increase to 366 million people by 2030. In particular, the number of people with diabetes in India,

currently around 40.9 million, is expected to rise to 69.9 million by 2030 (Wild *et al.*, 2004). Hyperglycaemia results from defects in insulin secretion, insulin action, or both (Gavin JR, 2003). Diabetes is also associated with hyperlipidaemia (De Sereday MS *et al.*, 2004; Krishnakumar *et al.*, 2000). One of the major pathogenesis of lipid metabolism disorders in diabetes is the increased mobilization of fatty acids from adipose tissues with secondary elevation of free fatty acids in the blood (Singh BM *et al.*, 1987). Currently available therapies for diabetes include insulin and various oral antidiabetic agents such as sulfonylureas, biguanides, α -glucosidase inhibitors, and glinides, which are used as monotherapy or in combination to achieve better glycemic regulation (Sy GY *et al.*, 2005). Many of these oral antidiabetic agents have numerous adverse effects. Hence, the management of diabetes without any side effects is still a challenge.

Corresponding Author

Anandakirouchenane E
Email: eakpharma@gmail.com

Nowadays, synthetic agents and insulin used for the treatment of diabetes have prominent side effects, which include hypoglycemia, drug resistance, dropsy, and weight gain. The use of traditional medicinal plants for the treatment of diabetes mellitus is widely practiced throughout the world. Many plant species are known in folk medicine of different cultures that possess hypoglycaemic properties and therefore used for the treatment of diabetes mellitus (Oliver BB & Zahnd GR, 1979). According to the World Health Organization (WHO), an estimated 3.5 billion people in the developing world depends on the medicinal plants as part of their primary health care (Balick MJ & Cox PA, 1966). The dried rhizomes of *Curculigo orchioides gaertner* (family Amarylladaceae), an endangered rasayana herb, is popularly known as “Kali Musli” (Rajagopalan *et al.*, 1995). The rhizomes of this plant possess medicinal as well as other properties and are effective against different diseases like diuretic, aphrodisiac, hemorrhoids, leucorrhoea, pruritis, skin diseases, asthma, bronchitis, jaundice, cancer, diarthrosis wound healing, etc. (Tanaka *et al.*, 2001). *Curculigo orchioides* possess various chemical constituents like flavones, glycosides, alkaloids, steroids, saponins, triterpenoids, and other secondary metabolites. Chauhan & Dixit VK (2007) have reported that the extract of *C. orchioides* rhizomes has been found to possess anti-hyperlipidemic activity (Misra *et al.*, 1984). Hence, in the present investigation, glucose-lowering and anti-hyperlipidaemic effects of the extract of *C. orchioides* rhizomes in alloxan-induced diabetic rat was evaluated by estimating the lipid profile and hyperglycemic factors such as blood glucose, serum insulin level, and oral glucose tolerance in an animal model.

MATERIALS AND METHODS

Chemicals

Alloxan monohydrate was purchased from Sigma Aldrich (St. Louis, MO., USA) stored at -4°C . Glibenclamide tablets were sourced from Daonil (Aventis Pharma. Ltd., India). All other chemicals used were procured from commercial suppliers and were of analytical grade.

Preparation of Extract

The root (rhizome) parts of *Curculigo orchioides* were collected, shade-dried, and then finely powdered (collected from the Bharathidasan University, Tamil Nadu). Around 500 gm of powder was extracted with methanol using a Soxhlet apparatus. The solvent was then evaporated under reduced pressure at 40°C and dried in a vacuum dessicator.

Experimental Animals

Adult male albino rats of the Wistar strain (170 - 190 grams) used in the present study were obtained from

Madras Veterinary College, TANUVAS, Chennai, India. The animals were housed in clean polypropylene cages under controlled temperature ($25\pm 2^{\circ}\text{C}$) with a 12/12-hr day–night cycle and free access to food and water *ad libitum*. Animal experimentation was carried out as per the rules and protocols approved by the Institutional Animal Ethical Committee (IAEC).

Induction of Diabetes

Rats were fasted overnight (12 hrs) and diabetes was induced by single intraperitoneal injection of alloxan (120mg/kg/b.w.). Induction of diabetes was confirmed by measuring blood glucose level 6 days after the administration of alloxan. Rats with blood glucose level ≥ 280 mg/dl were considered as diabetic and preferred for further experiment.

Experimental Design

The rats were divided into five groups of six animals in each group ($n = 6$).

- Group I: Normal control rats, which received vehicle alone.
- Group II: Diabetic control rats, which received 120mg/kg of alloxan [intra peritoneal injection (*ip*)].
- Group III: Normal rats, which received methanolic extract of *C. orchioides* orally (200 mg/kg/day.) for 21 days.
- Group IV: Diabetic rats, which received methanolic extract of *C. orchioides* orally (200 mg/kg/day.) for 21 days after alloxan treatment.
- Group V: Diabetic rats, which received glibenclamide orally (10mg /kg b.w/day) for 21 days.

The initial and final body weights of each rat were measured. On the 21st day, the animals were fasted for 14 hrs, anaesthetized, and sacrificed by decapitation. Blood was centrifuged at 2,700 rpms for 15-20 minutes at 4°C and serum was separated for biochemical assays. The pancreas were excised and fixed in 10% formalin for histopathological analysis.

Biochemical Estimation of Glucose, Glycosylated hemoglobin, and Insulin

The levels of blood glucose were estimated by enzymatic glucose oxidase method using a commercial kit (ERBA, India). Glycosylated haemoglobin in the blood was determined by the chromatographic–spectrophotometric ion-exchange method using a commercial diagnostic kit (Biosystems S. A., Barcelona, Spain). Serum insulin levels were estimated by solid phase enzyme-linked immunosorbent assay using a commercial kit (UBI Magiwell, Canada).

Oral Glucose Tolerance Test (OGTT)

Five days before the end of the experiment, oral glucose tolerance test (OGTT) was conducted to evaluate

the glucose tolerance. For this purpose, glucose (3g/kg. b.wt) was orally administered to each rat. Then, blood samples were collected from the tail vein at 0, 30, 60 and 90 min intervals after glucose administration.

Estimation of Lipid Profile in Blood Samples

Total cholesterol (GOD-POD method), high-density lipoprotein (HDL), triglycerides (TG), very-low-density lipoprotein (VLDL), and low-density lipoprotein (LDL) levels were measured by commercial kits (Biosystems S.A. Barcelona, Spain) using spectrophotometer in serum samples prepared as above. Cholesterol values were calculated as mg/dl blood sample.

Histological Studies

A small portion of each pancreas was fixed with 10% formalin for 24 hours at 37°C, dehydrated through a graded alcohol series, embedded in paraffin, sectioned at 5µm thickness, and stained with hematoxylin and eosin stain solution. Then, stained sections were mounted with DPX mountant and examined under Light microscope (Carl Zeiss, Germany).

Statistical Analysis

Results were expressed as Mean ± SD (n=6). Data were analyzed with one way ANOVA for the comparison between groups, followed by Duncan Multiple Range Test (DMRT) as a post hoc test. The significance level was set at $p < 0.05$.

RESULTS

Changes in Body Weight

Fig. 1 shows the differences in body weight between normal and diabetic rats. A gradual increase in body weight was observed in rats of Group I (normal rats), Group III (normal + *C. orchiooides* treated), and Group IV (diabetic + *C. orchiooides* treated). However, a significant decrease in body weight at day 0 was observed in rats dosed with alloxan (Group II, diabetic control). On the contrary, diabetic control rats (Group II) showed a progressive fall in body weight throughout the experimental period. Body weight gain in extract treated diabetic rats (group IV; diabetic + *C. orchiooides* treated) was significantly increased 21 days after dosing. The glibenclamide (10 mg/kg) treated group shows no significant changes compared to that of diabetic control rats.

Oral Glucose Tolerance Test

Fig.2 demonstrates the changes in the blood glucose level of normal and diabetic groups after oral glucose administration (3 g/kg b.wt). The results of OGTT revealed that the blood glucose levels in normal rats (Group I) reached peak at 90 min post glucose administration and steadily decreased to the preglucose load level. A superior glucose tolerance pattern was

observed in *C. orchiooides* extract treated rats (Group IV), when compared the normal control rats ($p < 0.05$). In diabetic control group (Group II), highly declined glucose tolerance was evident. Hence, Oral GTT suggests that, diabetic rats treated with *C. orchiooides* extract showed a prominent improvement in overall glucose response as compared to diabetic control and normal rats. Fasting blood glucose level was significantly higher for the diabetic group as compared to extract treated and control group of rats ($p < 0.05$).

Effects on Glucose Levels

The effect of methanolic extract of *C. orchiooides* rhizome on blood glucose level of alloxan-induced diabetic rats is presented in Fig. 3. From day 10 onwards, a significant glucose lowering potential was observed in diabetic rats treated with *C. orchiooides* rhizome extract. The reduction in blood glucose was significant on day 21 in extract treated diabetic rats (Group IV), compared with normal control rats (Group I), and the results were comparable with Group V rats receiving standard drug glibenclamide (10 mg/kg. b. wt). We observed an increased level of blood glucose in alloxan-induced diabetic rats. The anti-diabetic activity of methanol extracts of the rhizome was significant ($p < 0.05$) in decreasing blood glucose level.

Biochemical Findings

Methanolic extract of *C. orchiooides* significantly reduced ($p < 0.05$) the levels of serum total cholesterol, VLDL, LDL, and triglycerides in diabetic rats (Group IV) compared to that of diabetic control rats (Group II). The level of HDL was significantly increased (Fig. 4; $p < 0.05$) in extract treated rats whereas, control diabetic rats showed a lower level of HDL after 21 days of experiment.

Changes in Histopathology of the Pancreas

Histopathology of pancreatic tissue revealed that the cells of diabetic control animals were irregular and not well defined and contained reduced number of islets and defects in cell membrane. Necrosis of the cell was very clear (Group II, Fig. 5 B). The standard drug glibenclamide treated group showed a moderate protection from alloxan-induced changes in the pancreatic islets (Group V, Fig. 5E). Treatment of diabetic rats with *C. orchiooides* showed improvement in the β -cells protective effect on the pancreatic architecture similar to that of the normal animals with many round and elongated islets evenly distributed throughout the cytoplasm, whereas the surrounding acinar cells and their nucleus being more lightly stained (Group IV, Fig. D).

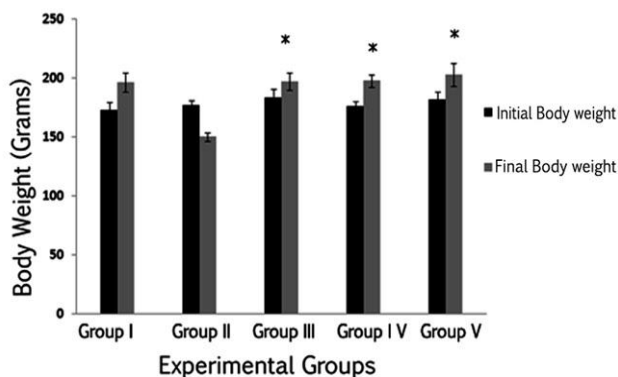
Effect on Serum Glycosylated Haemoglobin and Insulin Level

Fig. 6 & 7 show the changes in glycosylated haemoglobin (HbA1C) and insulin of normal and experimental rats. The *C. orchioides* treated diabetic rats show a significant decline in glycosylated haemoglobin (Group IV, $p < 0.05$) and an increase in the levels of insulin compared to that of diabetic control rats (Group II). Meanwhile, diabetic control rats show a significant

($P < 0.05$) increase in glycosylated haemoglobin and a significant ($P < 0.05$) decrease in serum insulin, compared to that of untreated (Group I) and extract treated (Group III) rats. The results show the administration of *C. orchioides* reduced the HbA1C and increased the insulin levels in alloxan-induced diabetic rats similar to normal control rats (Group I).

Fig. 1. Effect of methanolic extract of *C. orchioides* on body weight in normal and alloxan induced diabetic rats.

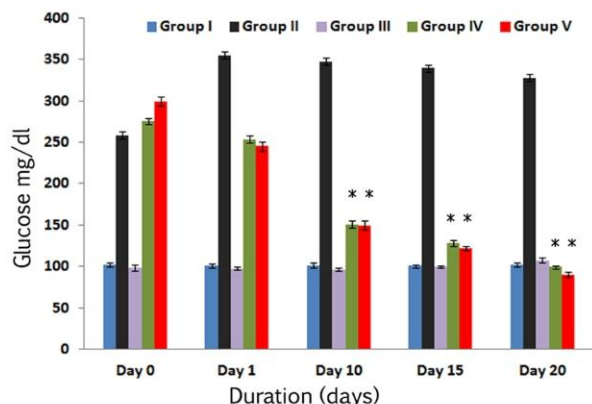
Fig. 1



Values represent the mean \pm SD of the observations made on six rats in each group. Statistical analysis: one-way analysis of variance [ANOVA] with post-hoc testing [least significant difference]. * Statistically significant difference ($P < 0.05$) when compared with Group I and Group III values. * Statistically significant difference ($P < 0.05$) when compared with Group II values.

Fig. 3. Levels of Glucose in normal, diabetic and extract treated rats at different time intervals (0, 1, 10, 15 and 20 days)

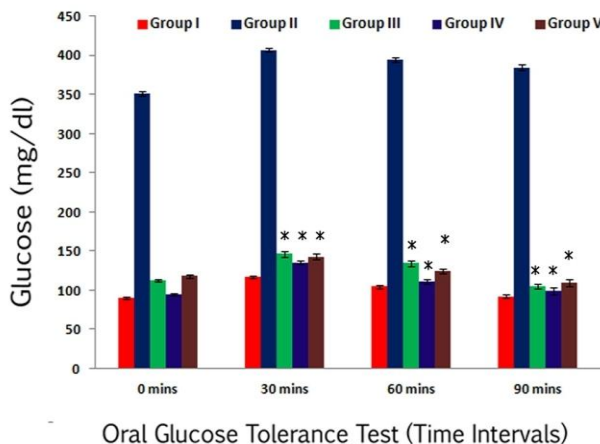
Fig. 3



Values represent the mean \pm SD of the observations made on six rats in each group. Statistical analysis: one-way analysis of variance [ANOVA] with post-hoc testing [least significant difference]. * Statistically significant difference ($P < 0.05$) when compared with Group I and Group III values. * Statistically significant difference ($P < 0.05$) when compared with Group II values.

Fig. 2. Oral Glucose Tolerance Test (OGTT)

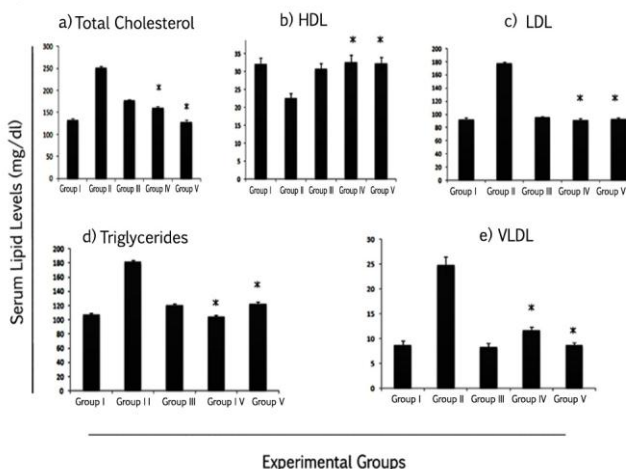
Fig. 2



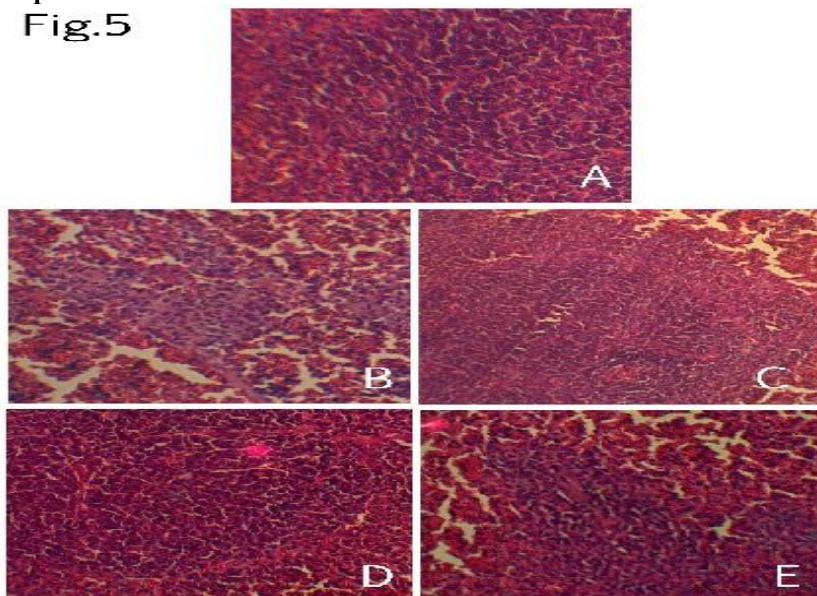
Values represent the mean \pm SD of the observations made on six rats in each group. Statistical analysis: one-way analysis of variance [ANOVA] with post-hoc testing [least significant difference]. * Statistically significant difference ($P < 0.05$) when compared with Group I and Group III values. * Statistically significant difference ($P < 0.05$) when compared with Group II values.

Fig. 4. (a - e) Effect of methanolic extract of *C. orchioides* on serum lipid profile

Fig. 4



Values represent the mean \pm SD of the observations made on six rats in each group. Statistical analysis: one-way analysis of variance [ANOVA] with post-hoc testing [least significant difference]. * Statistically significant difference ($P < 0.05$) when compared with Group I and Group III values. * Statistically significant difference ($P < 0.05$) when compared with Group II values.

Fig. 5. Histopathology of pancreatic islet tissue from Diabetic and *C. orchioides* treated rats

Histoarchitecture of pancreatic tissues of hematoxylin-eosin staining, $\times 100$ magnification. A) Control rat showing normal pancreatic histo-architecture. B) Diabetic control rat showing irregular reduced number of islets, and defects in cell membrane. C) Normal rats treated with extract showing no alterations D) Diabetic rats treated with extract shows preservation of almost normal profile of the β -cells. E) The standard drug glibenclamide treated rat showing a moderate protection from alloxan induced changes in the pancreatic islets.

Fig. 6 & 7. Effect of methanolic extract of *C. orchioides* on Insulin and Glycosylated hemoglobin level

Fig. 6

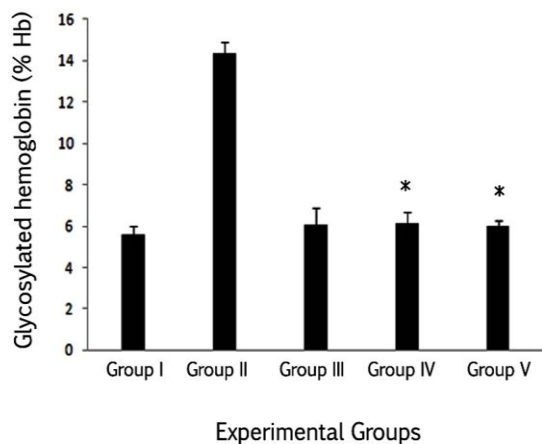
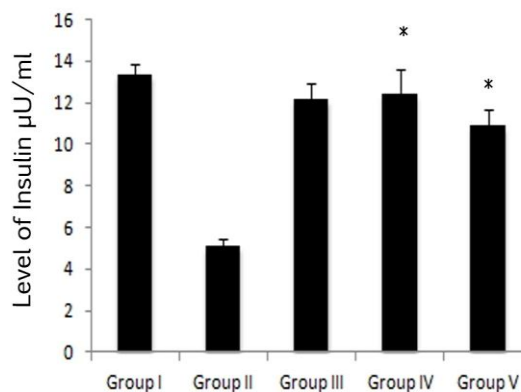


Fig. 7



Values represent the mean \pm SD of the observations made on six rats in each group. Statistical analysis: one-way analysis of variance [ANOVA] with post-hoc testing [least significant difference] * Statistically significant difference ($P < 0.05$) when compared with Group I and Group III values. * Statistically significant difference ($P < 0.05$) when compared with Group II values.

DISCUSSION

Alloxan-induced diabetes is characterized by a severe loss in body weight (Marles RJ & Farnsworth NR, 1995) and this reduction is due to the loss or degradation of structural proteins, which was observed in the diabetic group. A significant gain in body weight was observed in the groups treated with methanol extract of the plant *C.*

orchioides. The current study focuses on the anti-diabetic effect of methanolic extract of *C. orchioides* in alloxan-induced diabetic rats. The mechanisms by which alloxan brings about its diabetic state include selective destruction of pancreatic insulin secreting beta cells, which make cells less active (Chauhan NS & Dixit VK, 2007) and lead to poor glucose utilization by tissues (Junod *et al.*, 1969).

There were neither lethal effects nor toxic reactions found in the treated rats until the end of the study period (21 days). Oral GTT data over 90 min suggest that *C. orchioides* extract reduced glucose concentration in diabetic rats. Glucose tolerance activity of *C. orchioides* may be through the stimulation of surviving β -cells of islets of langerhans to release more insulin. A number of other plants have been observed to exert antidiabetic activity through insulin-release stimulatory effects such as *Tinospora cord folia* (Bagepalli *et al.*, 2010; Stanley *et al.*, 2000). The methanolic extract of *C. orchioides* significantly reduced the high fasting glucose levels in diabetic rats. This suggests that the extracts may possess insulin like effect on peripheral tissues by either promoting glucose uptake or metabolism, by inhibiting hepatic gluconeogenesis (Cherian *et al.*, 1992) or absorption of glucose into the muscles and adipose tissues (Ali *et al.*, 1993), by the stimulation of a regeneration process, and revitalization of the remaining beta cells (Kamanyi *et al.*, 1994). In diabetes, hyperglycemia is accompanied with dyslipidemia (Shanmugasundaram *et al.*, 1990; Bierman *et al.*, 1996) representing risk factor for coronary heart diseases. The level of serum lipids is usually elevated in diabetes, and such an increase represents a vulnerable factor for coronary heart diseases (Murali *et al.*, 2002). The alterations in plasma glucose and lipid profile seen in treated animals could be beneficial in preventing diabetic complications as well as in improving lipid metabolism in diabetics. The abnormal high level of serum lipids is mainly due to the uninhibited actions of lipolytic hormones on the fat deposits mediated by the action of insulin. Under physiological condition, insulin triggers the enzyme lipoprotein lipase, which hydrolyses triglycerides. Nevertheless, in diabetic state, lipoprotein lipase is suppressed due to insulin deficiency, culminating in hyper triglyceridemia and insulin deficiency, which is associated with hyper cholesterolemia due to metabolic abnormalities (Mironava *et al.*, 2000). The dyslipidemia is characterized by an increase in total cholesterol (TC), low density lipoprotein (LDL), very low density lipoprotein (VLDL),

REFERENCES

- Ali L, Azad Khan AK, Mamun MIR, Mosihuzzaman M, Nahar N, Nur-E-Alan M, Rokeya B. *Planta Medica*, 59, 1993, 408–412.
- Ayber MJ, Riera AN, Grau A, Sanchez SS. Hypoglycemic effect of the water extract of *Smallantus sonchifolius* (yacon) leaves in normal and diabetic rats. *J Ethnopharmacol*, 74, 2001, 125-132.
- Bagepalli SAK, Kuruba L, Jayaveera KN, Devangam SS, Avalakondarayappa AK, Bachappa M. Antioxidant and antipyretic properties of methanolic extract of *Amaranthus spinosus* leaves. *Asian Pac J Trop Med*, 3(9), 2010, 702-706.
- Balick MJ, Cox PA. *Plants, People and Culture, The Science of Ethnobotany*, WH Freeman and Company, Scientific American Library, New York 1996.
- Bierman EL, Amaral JAP, Belknap BH. Hyperlipidemia and diabetes. *Diabetes*, 15, 1996, 675-679.
- Chauhan NS, Dixit VK. Antihyperglycemic activity of the ethanolic extract of *Curculigo orchioides* Gaertn. *Pharmacognosy Magazine*, 3, 2007, 237-240.

and triglycerides (TG) and a fall in high density lipoprotein (HDL) (Pushparaj *et al.*, 2007). This imbalance in serum lipid profile was reversed towards normal rats after treatment with methanolic extract of *C. orchioides*. The diabetic untreated rats revealed degeneration of pancreatic islet cells, which was due to the usage of alloxan in this experiment. However, signs of regeneration of β -cells have been reported following consumption of plant extracts (Padalkar *et al.*, 2012; Ayber *et al.*, 2001). Haemoglobin is highly susceptible to non-enzymatic glycation. In diabetic control rats, the excess blood glucose reacts non -enzymatically with haemoglobin to form glycated haemoglobin (HbA1c), which has altered the affinity for oxygen and this may be a factor in tissue anoxia. Measurement of HbA1c is an effective means to screen glycemic control in diabetic control rats (Yadev *et al.*, 2008). The alloxan-induced rats illustrate low level of insulin release in response to glucose due to the depletion of pancreatic β -cell (Okamoto H, 1981). This suggests that *C. orchioides* may protect the pancreatic β -cell and increase insulin secretion.

CONCLUSION

From this study, it is concluded that methanolic extracts of *C. orchioides* extract confirm that it has superior antihyperglycemic and antihypolipidemic properties.

ACKNOWLEDGEMENT

The authors would like to thank Mr. C. Srinivasa Baba, President, Gokula Krishna College of Pharmacy, for permitting to do the experimental part, and acknowledge the Instrumentation Facility established through UGC-SAP and DST-FIST, Department of Animal Science, Bharathidasan University, Tiruchirappalli - 620 024.

CONFLICT OF INTEREST

The authors declare that there is no conflict of interest.

- Cherian S, Kumar RV, Augusti KT, Kidwai JR. Antidiabetic effect of a glycoside of Pelargonin isolated from the bark of *Ficus bengalensis* Linin. *Indian J Biochem. Biophysics*, 29, 1992, 380-382.
- De Sereday MS, Gonzalez C, Giorgini D, De Loredo L, Braguinsky J, Cobenas C. Prevalence of diabetes, obesity, hypertension and hyperlipidemia in the central area of Argentina. *Diabetes and Metab*, 30, 2004, 335-339.
- Gavin JR. Report of the expert committee on the diagnosis and classification of diabetes mellitus. *Diabetes Care*, 26, 2003, 5-19.
- Junod A, Lambert AE, Stauffacher W, Renold AE. Diabetogenic action of streptozotocin of dose to metabolic response. *J Clin Invest*, 48, 1969, 2129-2139.
- Kamanyi A, Djamen D, Nkeh B. Hypoglycemic properties of the aqueous roots extract of *Morinda lucida* (Rubiaceae) study in the mouse. *Phytother Res*, 8, 1994, 369-371.
- Krishnakumar K, Augusti KT, Vijayammal PL. Antiperoxidative and hypoglycemic activity of *Sulacia oblonga* extract in diabetic rats. *Pharmaceutical Biol*, 38, 2000, 101-105
- Marles RJ, Farnsworth NR. Antidiabetic plants and their active constituents. *Phytomedicine*, 22, 1995, 123-189.
- Mironava MA, Klein RL, Virella GT, Lopes-Virella MF. Anti-modified LDL antibodies, LDL-containing immunone complexes, and susceptibility of LDL to in vitro oxidation in patients with type 2 diabetes. *Diabetes*, 49, 2000, 1033-49.
- Misra TN, Singh RS, Upadhyaya J, Tripathi DNN. Aliphatic compounds from *Curculigo orchioides*. *Phytochemistry*, 23, 1984, 1643-1645.
- Murali B, Upadhyaya UM, Goyal RK. Effect of chronic treatment with *Enicostemma littorale* in non-insulin dependent diabetic (NIDDM) rats. *J Ethnopharmacol*, 81, 2002, 199-204.
- Mutalik S, Sulochana B, Chetana M, Udupa N, Uma Devi P. Preliminary studies on acute and subacute toxicity of an antidiabetic herbal preparation, Dianex. *Indian J Exp Biol*, 41, 2003, 316-320.
- Okamoto H. Regulation of proinsulin synthesis in pancreatic islets and a new aspect to insulin dependent diabetes. *Mol Cell Biochem*, 37(1), 1981, 43-61.
- Oliver BB, Zahnd GR. Plants with oral hypoglycaemic action. *Quarterly Journal of Crude Drug Research*, 17, 1979, 139-196.
- Padalkar RK, Shinde AV, Patil SM. Lipid profile, serum malondialdehyde, superoxide dismutase in chronic kidney diseases and type 2 diabetes mellitus. *Biomed Res*, 23, 2012, 207-210.
- Pushparaj PN, Low HK, Manikandan J, Tan BK, Tan CH. Antidiabetic effects of *Cichorium intybus* in STZ-induced diabetic rats. *J Ethnopharmacol*, 111, 2007, 430-434.
- Rajagopalan K, Sivarajan VV, Varier PR. *Curculigo orchioides* Gaertn. In: Indian Medicinal Plants, eds: Warriar PK, Ramankutty C. *Orient Longman*, 2, 1995, 245-248.
- Rungeesantivanon S, Thenchaisri N, Ruangvejvorachai P, Patumraj S. Curcumin supplementation could improve diabetes-induced endothelial dysfunction associated with decreased vascular superoxide production and PKC inhibition. *BMC Complement Altern Med*, 10, 2010, 57.
- Shanmugasundaram ERB, Gopinath KL, Shanmugasundaram KR, Rajendran VM. Possible regeneration of the islets of Langerhans in streptozotocin-diabetes rats given *Gymnema sylvestre* leaf extracts. *J Ethnopharmacol*, 30, 1990, 265-279.
- Singh BM, Palma MA, Natrass M. Multiple aspects of insulin resistance. Comparison of glucose and intermediary metabolite response to incremental insulin infusion in IDDM subjects of short and long duration. *Diabetes*, 36, 1987, 740-748.
- Stanley P, Prine M, Menon VP. Hypoglycemic and other related actions of *Tinospora Cordifolia* in alloxan-induced diabetic rats. *J Ethnopharmacol*, 70, 2000, 9-15.
- Sy GY, Cisse A, Nongonierma RB, Sarr M, Mbodj NA, Faye B. Hypoglycaemic and antidiabetic activity of acetonic extract of *Vernonia colorata* leaves in normoglycaemic and alloxan-induced diabetic rats. *J Ethnopharmacol*, 98, 2005, 171-175.
- Tanaka Y, Atsumi Y, Matsuoka K, Mokubo A, Asahina T, Hosokawa K, Shimada S, Matsunaga H, Takagi M, Ogawa O, Onuma T, Kawamori R. Usefulness of stable HbA1c for supportive marker to diagnose diabetes mellitus in Japanese subjects. *Diabetes Res Clin Pract*, 53(1), 2001, 41-45.
- Taskinen MR. Diabetic dyslipidemia. *Atherosclerosis*, 3, 2002, 47-51.
- Wild S, Roglic G, Green A, Sicree R, King H. Global prevalence of diabetes: estimates for the year 2000 and projections for 2030. *Diabetes Care*, 27, 2004, 1047-1053.
- Yadev JP, Saini S, Kalia AN, Dangi AS. Hypoglycemic and hypolipidemic activity of ethanolic extract of *Salvadora oleoides* in normal and alloxan-induced diabetic rats. *Indian J Pharmacol*, 40, 2008, 23-27.