



PROTECTIVE EFFECT OF FRUITS OF *PEDALIUM MUREX* AGAINST GENTAMICIN -INDUCED NEPHROTOXICITY IN RATS.

A. Sreedevi*, Y. Jyothi Prasanna Latha, K. Bharathi

*Institute of Pharmaceutical Technology, Sri Padmavathi Mahila Viswavidyalayam Tirupati-517502.

ABSTRACT

The present study aimed to evaluate the nephroprotector activity of the ethanolic and aqueous extracts of fruits of *Pedaliium murex* (600mg/kg body weight, p.o.) against gentamicin-induced (100mg/kg/d s.c.) renal toxicity in rats. The effect of plant extracts were examined by estimating blood urea nitrogen, serum creatinine, urinary protein, urine to serum creatinine ratio, lipid peroxidation, glutathione, catalase in kidney. In present study, gentamicin-induced nephrotoxicity characterized by significant elevation of serum markers levels, increased urinary protein excretion, raised LPO levels, reduced GSH and CAT levels, reduced creatinine clearance. Co-administration of either ethanolic or aqueous extract with gentamicin was significantly prevented the renal injury protection both functionally and histological in dose dependent manner. The present study provides the corroborative scientific evidence for the folklore use of *Pedaliium murex* in urinary troubles.

Key words: Gentamicin, *Pedaliium murex*, Nephrotoxicity.

INTRODUCTION

Gentamicin (GM) is an aminoglycoside antibiotic commonly used in treating life-threatening gram-negative bacterial infections (Ali, 1995). However, 30% of the patients treated with GM for more than 7 days show some signs of nephrotoxicity (Mathew, 1992), and serious complications resulting from GM-induced nephrotoxicity is a limiting factor for its clinical usage. GM is not metabolized in the body but is essentially eliminated by glomerular filtration and partially reabsorbed by proximal tubular cells (Black *et al.*, 1963; Silverblatt *et al.*, 1979). Gentamicin-induced kidney damage is characterized by tubular necrosis, primarily localized to the proximal tubule. This might be explained by an increased kidney uptake of the antibiotic, mainly at the proximal tubular level (Beauchamp *et al.*, 1985).

Although gentamicin's effect on biological membranes appears to be critical in the pathogenetic events of gentamicin (GEN) toxicity (Humes *et al.*, 1982), the exact mechanisms of gentamicin nephrotoxicity is unknown; however, GEN has been shown both *in vitro* and *in vivo* studies to enhance the generation of reactive oxygen species (ROS). Abnormal production of ROS may damage some macromolecules, to induce cellular injury and necrosis *via* several mechanisms including peroxidation of membrane lipids, protein denaturation and DNA damage, and this is believed to be involved in the etiology of many xenobiotics toxicity (Baliga *et al.*, 1999; Kehrer, 1993; Nakajima *et al.*, 1994; Parlakpinar *et al.*, 2005). The alteration in kidney functions induced by lipid peroxidation is a proximal event in the injury cascade of GEN nephrotoxicity. Some investigators showed that GEN acts as an iron chelator, and that the iron-GEN complex is a potent catalyst of free radical formation (Priuska and Schacht, 1995; Yanagida *et al.*, 2004). Several studies have demonstrated that various agents including melatonin (Ozbek *et al.*, 2000), vitamin E, superoxide dismutase (SOD) (Pedraza-Chaverri *et al.*,

Corresponding Author

A. Sreedevi

E mail: sridevitirupati@rediffmail.com

2000), lipoic acid (Al-Majed *et al.*, 2002; Sandhya and Varalakshmi, 1997), zinc (Kumar *et al.*, 2000), *ginkgo biloba* extract (Maldonado *et al.*, 2003), diallyl disulfide (Pedraza-Chaverr'y *et al.*, 2003) and plants containing anti oxidants principles, such as *Scoporia dulcis* (Adaikpoh *et al.*, 2007), Grape Seed Proanthocyanidin extracts (Ray *et al.*, 2006), *Rheum emodi* (Azhar Alama., 2005), *Withania somnifera* (Panda *et al.*, 1997) can prevent GEN-induced renal damage. *Petalium murex* (*P. murex*) is one such plant containing triterphenoids, fatty acids, steroids and flavonoids and also used to treat rheumatism, urinary calculi and renal troubles by village folk of Rayalaseema (Thammanna and Narayana Rao, 1990; Vedavathy 1997). To date there is no study the protective effect of *P. murex* a known diuretic (Singh *et al.*, 1999, Sangeetha *et al.*, 1993) on renal toxicity induced by GEN. Hence, the present study was designed for systematic pharmacological evaluation of fruits of *P. murex* against experimentally renal damage induced by gentamicin.

MATERIALS AND METHODS

Plant material: Fruits of *Petalium murex* were collected from Talakona, chittor district, Andhra Pradesh, India in the month of August-December, 2007 and authenticated by botanist Dr. Madhava chetty, Herbarium keeper, Department of botany, Sri venkateswara university, Tirupati, India and a specimen (Specimen No:862) has been deposited in Department of botany, Sri venkateswara university, Tirupati, India.

Preparation of Plant extracts

***Petalium murex* Ethanol Extract (PEE):** The fruits were allowed to dry under shade. The dried fruits (500 g) were powdered in a Wiley mill and extracted with rectified spirit (4L x3). The extract was concentrated under reduced pressure to get solid mass 40g (8%).

***Petalium murex* Aqueous Extract (PAE):** Fruit powder (400g) was boiled with water (2.5L) for 30 min, cooled, kept overnight at room temp (25± 2°C) and filtered. The filtrate was concentrated (100 mg/ml) and was used for the present study.

Animals: Healthy wistar adult male albino rats between 2 and 3 months of age and weighing about 150-200g were used to the study. Housed in polypropylene cages and fed with standard rat pellet diet, water *ad libitum*. Animals were acclimatized to our lab environment for about a week. The study was conducted after obtaining Institutional ethical committee clearance.

Effect of PEE and PAE in normal rat kidney

The animals were divided into three groups of six rats each randomly.

- Animals of group I (control) received 2% gum acacia in distilled water (10 ml/kg/d) for 8 days.
- Animals of group II_{PEE} received PEE (600 mg/kg) suspended in the vehicle (10 ml/kg) for 8 days.
- Animals of group III_{PAE} received PAE (600 mg/kg) suspended in the vehicle (10 ml/kg) for 8 days.

Effect of PEE and PAE in gentamicin-induced kidney damage in rats

The rats were divided into four groups of six animals each.

- Animals of group I received 2% gum acacia (10 mg/kg/d) for 8 days.
- Animals of group II received 2% gum acacia in distilled water (10 ml/kg) for 8 days.
- Animals of group III received PEE (600 mg/kg) suspended in the vehicle (10 ml/kg) for 8 days.
- Animals of group IV received PAE (600 mg/kg) suspended in the vehicle (10 ml/kg) for 8 days.
- Animals of group V received Vitamin E (100 mg/kg) suspended in the vehicle (10 ml/kg) for 8 days.

In addition to this, the animals in groups II, III IV and V were co-administered subcutaneously daily with gentamicin in a dose of 100 mg/kg, in neck region in a volume of 1 ml/kg for last 5 days (Niazi, 1994). Animals of group I was given normal saline (s.c.) instead of Gentamicin.

On the day 9, urine was collected with the help of metabolic cages and the urine samples were subjected for estimation of urinary functional parameters. The animals were sacrificed by cervical decapitation and blood samples were collected by cardiac puncture and were used for estimation of serum markers.

Nephroprotector Activity was assessed by estimating Blood Urea Nitrogen (BUN) by DAM method [Godkar 1994], Serum Creatinine (SC) by Jaffe's Alkaline Picrate method [Godkar 1994], and Urinary Total Proteins (U_{TP}) by Turbidimetry method, Urinary Creatinine (Ucr) by alkaline picrate Method (Godkar, 1994), Creatinine Clearance (Clcr) Clcr was calculated by using formula

Creatinine clearance = Urinary creatinine X urinary volume/hr/ Serum creatinine.

Lipid Peroxidation Activity (LPO) (Ohkawa, 1979), Glutathione Activity (GSH) (Ellman, G., 1959), Catalase activity (CAT) (Cohen *et al.*, 1970) in kidney tissue.

IN VITRO ANTIOXIDANT STUDIES

Nitric Oxide Scavenging Activity

Nitric Oxide Scavenging Activity was tested for both aqueous and alcoholic extracts of roots of *P. murex*. Sodium

nitroprusside (5 mM) was mixed with different concentrations of alcoholic or aqueous extracts of roots of *P. murex* (50, 100, 200, 300, 400, 500 and 600 µg/ml) and incubated at 25°C for 5 hr. After 5 hr Griess reagent (2 ml of 2% o-phosphoric acid, 1 gram of suphthylamide, 100 mg of n-naphthylethylene-diamine made up to 100 ml) was added and absorbance of the chromophore formed was read at 546 nm. Control experiments were also carried out in a similar manner. The experiments were conducted in triplicate. Percentage scavenging effect was calculated (Green *et al.*, 1982; Marcocci *et al.*, 1994).

DPPH Radical Scavenging Activity

DPPH Radical Scavenging Activity was tested for both aqueous and alcoholic extracts of roots of *P. murex*. To an ethanolic solution of DPPH (200 mM), 0.05 ml of ethanolic or aqueous extracts dissolved in ethanol were added at different concentrations (100-600 mg/ml). An equal amount of ethanol/water was added to the control after 20min the decrease in absorbance of test mixtures was read at 517 nm and the percentage inhibition calculated (Blio, 1958).

Statistical Analysis: The statistical data was presented as mean \pm SEM, Parametric data which include all the biochemical parameters were analyzed using a paired *t* test for the paired data or one way analysis of variance (ANOVA) followed by a Dun net multiple comparisons post test. A probability value of $P < 0.05$ was considered as significant. **RESULTS:**

Effect of *P. murex* fruit extracts on normal rat kidney:

Animals which received the PEE (group II_{PEE}) and animals which received the PAE (III_{PAE}) alone for eight days exhibited no change in serum markers level, urinary functional parameters and antioxidant enzyme levels. Hence, the alcoholic extract and aqueous extracts did not show any deteriorative effects on kidney (Table-1 & 2).

Effect of PEE and PAE on Gentamicin-induced nephrotoxicity

Table-3 lists the effect of PEE and PAE on Gentamicin-induced nephrotoxicity.

Effect on Serum markers

Rats which received GM 100 mg/kg/s.c alone showed significant increase in the levels of BUN and SC when compared to normal control animals. Animals which treated with PEE (Gr-III), PAE (Gr-IV) showed significant protection against elevation of BUN and SC levels when compared to respective control group animals

and values of rats fed with PAE at 600 mg/kg dose showed nearer values to that of animals which received Vit.E. These two group values are closer to Gr-1 animals (Table-2).

Effect on Urinary functional parameters

Daily s.c. administration of GM at 100 mg/kg for 5 days caused renal dysfunction in Gr-II animals as evidenced by increased urinary protein excretion and decreased Clcr when compared to normal control animals. Co-administration of PEE (Gr-III), PAE (Gr-IV) and Vit.E (Gr-V) with GM decreased urinary protein excretion and increased Clcr. Rats fed with PAE showed nearer values to that Vit.E fed rats. These two group values are closer to Gr-I animals (Table-4).

Effect on *In vivo* antioxidant activity

Animals which received GM (Gr-II) alone, showed increased levels of LPO (122.46 \pm 4.6), decreased levels of GSH (6.38 \pm 0.15) and CAT (0.15 \pm 0.25) when compare to normal control animals (64.67 \pm 3.5, 12.19 \pm 0.13 and 1.64 \pm 0.31). Animals which received PEE (Gr-III), PAE (Gr-IV) and Vit.E (Gr-V) respectively exhibited decrease in LPO (82.42 \pm 3.3, 70.52 \pm 2.49, 65.54 \pm 2.34), increase in GSH (11.48 \pm 0.17, 12.1 \pm 0.14, 12.32 \pm 0.12) and CAT (1.38 \pm 0.19, 1.51 \pm 0.37, 1.59 \pm 0.26) levels (fig-7, 8, 9).

Histological studies

The section of the Kidneys isolated from rats treated with GM alone exhibited marked Hemorrhages, picnotic changes and necrotic tubular epithelial cells indicating GM-induced renal necrosis. Animals which were treated with PAE and Vit.E showed marked protection against GM toxicity, characterized by regenerative changes in glomeruli and tubular epithelial cells and the animals which received PEE exhibited moderate protection indicated by mild hemorrhages, glomerular atrophy.

IN VITRO ANTIOXIDANT STUDIES

Nitric Oxide Scavenging Activity

Ethanolic and the aqueous extracts of fruits of *p.murex* were taken in different concentrations i.e 100, 200, 300, 400, 500, 600 µg/ml in sodium nitroprusside. The absorbance was measured at 546 nm by addition of Griess reagent. Both the extracts exhibited good nitric oxide scavenging activity and the activity was concentration dependent. ethanolic and aqueous extracts at 600 µg/ml concentration showed maximum nitric oxide scavenging activity i.e., 55 and 57% respectively (Fig-4).

DPPH Activity

DPPH is a relatively stable free radical and this assay determines the ability of *P. murex* extracts (100-600 µg/ml) to reduce DPPH radical to the corresponding hydrazine by converting the unpaired electrons to paired

ones. Fig-5 indicates ability of PEE and PAE to reduce DPPH radical. Activity was concentration dependent. At 600 µg/ml concentration both the extracts showed highest reduction of DPPH radical (64% & 67%) in a stoichiometric manner (Fig-5).

Table 1. Effect of ethanolic and aqueous extracts of *p.murex* on Normal rats

Group	Treatment mg/kg)	BUN (mg/dl)	SC (mg/dl)	U _{TP} (mg/24hrs)	Clcr (ml/hr/100g bd.wt)
I.	Normal	23.28±0.16	0.66±0.14	7.20±0.33	18.0±1.5
II _{PEE}	PEE (600mg/kg)	24.24±0.19 [#]	0.67±0.01 [#]	7.26±0.19 [#]	18.8±1.7 [#]
III _{PAE}	PAE (600mg/kg)	23.90±0.13 [#]	0.66±0.15 [#]	7.28±0.16 [#]	18.3±1.9 [#]

Each value represents the mean ± S.E.M from 6 animals in each group.

NS When compared with Normal.

PEE –*P.murex* ehanolic extract

PAE–*P.murex* aqueous extract

Table 2. Effect of ethanolic and aqueous extracts of *p.murex* on Normal rats

Group	Treatment (mg/kg)	LPO (nmol min ⁻¹ mg tissue ⁻¹)	GSH (µmol min ⁻¹ mg tissue ⁻¹)	CAT (K/ min)
I.	Normal	64.58±2.13	12.14±0.13	1.64±0.12
II _{PEE}	PEE (600mg/kg)	66.28±3.07 [#]	12.56±0.10 [#]	1.53±0.09 [#]
III _{PAE}	PAE (600mg/kg)	65.25±3.10 [#]	12.44±0.17 [#]	1.66±0.15 [#]

Each value represents the mean ± S.E.M from 6 animals in each group.

NS When compared with Normal.

PEE –*P.murex* ehanolic extract

PAE–*P.murex* aqueous extract

Table 3. Effect of ethanolic and aqueous extracts of fruits of *p.murex* on Gentamicin-induced nephrotoxicity

Group	Treatment mg/kg	BUN (mg/dl)	SC (mg/dl)	U _{TP} (mg/24hrs)	Clcr (ml/hr/100g bd.wt)
I.	Normal	23.4 ± 3.5	0.67±0.01	7.25±0.37	18.0±1.5
II.	GM 100 mg/kg	45.36±3.2*	2.57±0.01*	18.38±0.22*	6.4±0.9*
III.	PEE (600) + GM	28.6±1.8 ^{ab}	1.04±0.04 ^{ab}	10.6±0.33 ^{ab}	16.9±1.3 ^{ab}
IV.	PAE (600) +GM	25.64±1.5 ^{ab}	0.70±0.01 ^{ab}	8.28±0.48 ^{ab}	17.9±1.20 ^{ab}
V.	Vit. E (100mg/kg+GM)	24.22±2.5 ^a	0.71±0.0 ^a	7.22±0.45 ^a	18.2±1.90 ^a

Each value represents the mean ± S.E.M from 6 animals in each group.

*P<0.05 when compared with normal control group

a : P<0.05 when compared with control group(CdCl₂)

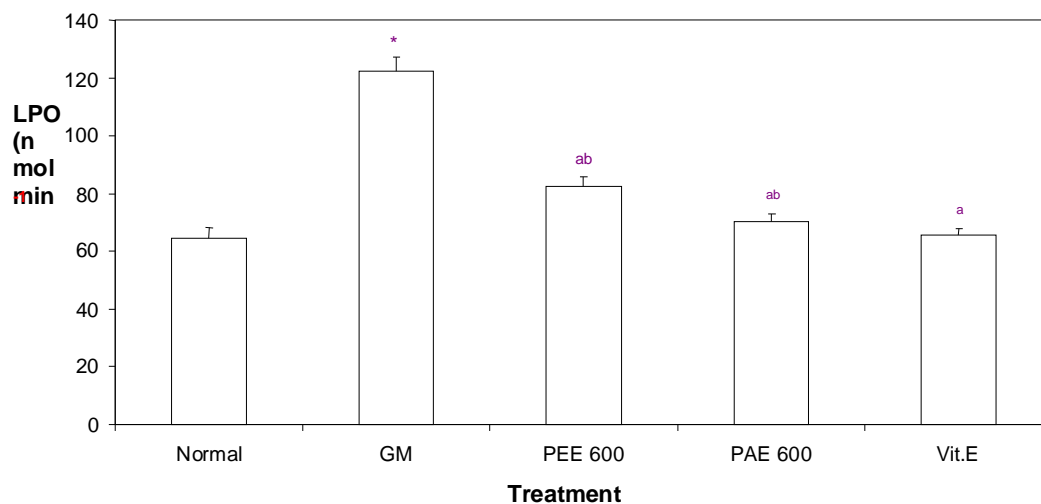
b : P<0.01 when compared with Std group

PEE – *P.murex* ehanolic extract

PAE– *P.murex* aqueous extract

GM- Gentamicin

Fig 1. Effect of ethanolic and aqueous extracts of fruits of *P. murex* On LPO in GM-induced nephrotoxicity



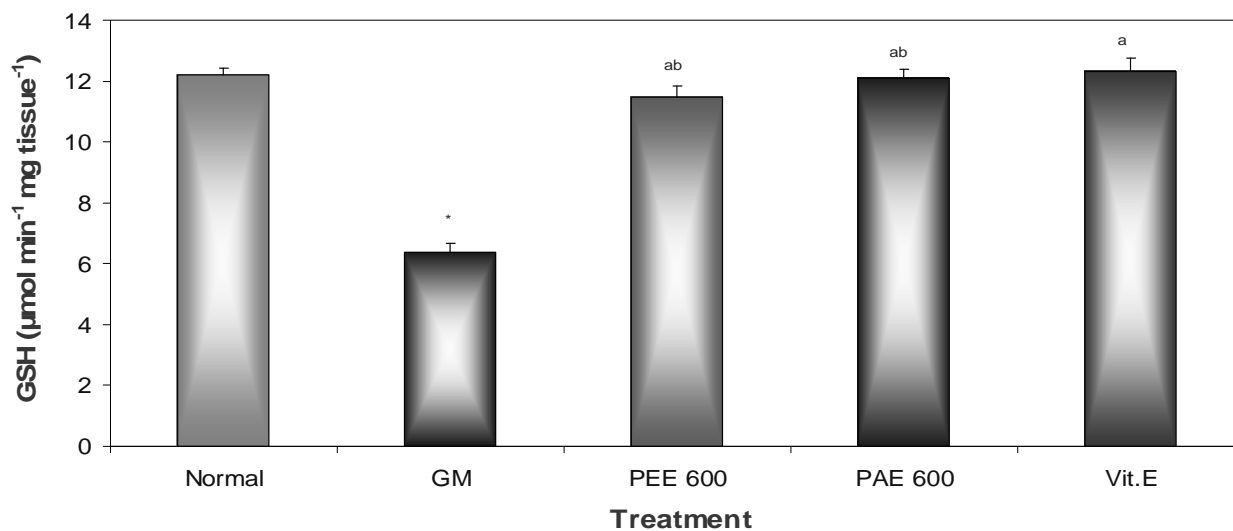
Each value represents the mean \pm S.E.M from 6 animals in each group.

*P<0.05 when compared with normal control group

^aP<0.05 when compared with control group (CdCl₂)

^bP<0.01 when compared with Std group

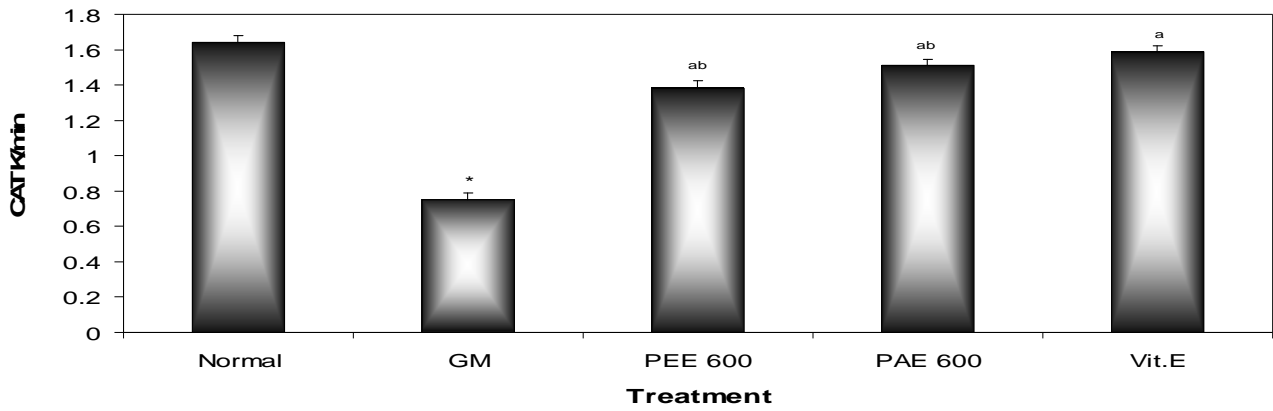
Fig-8: Effect of ethanolic and aqueous extracts of fruits of *P. murex* on GSH in GM-induced nephrotoxicity



Each value represents the mean \pm S.E.M from 6 animals in each group.

*P<0.05 when compared with normal control group:^aP<0.05 when compared with control group (GM):^bP<0.01 when compared with Std group

Fig-9: Effect of ethanolic and aqueous extracts of fruits of *P. murex* on CAT in GM-induced nephrotoxicity



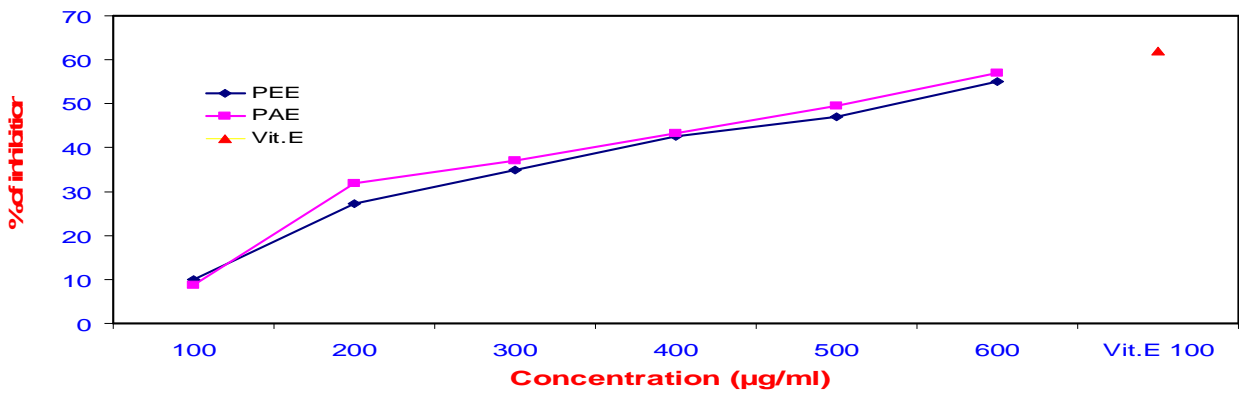
Each value represents the mean ± S.E.M from 6 animals in each group.

*P<0.05 when compared with normal control group

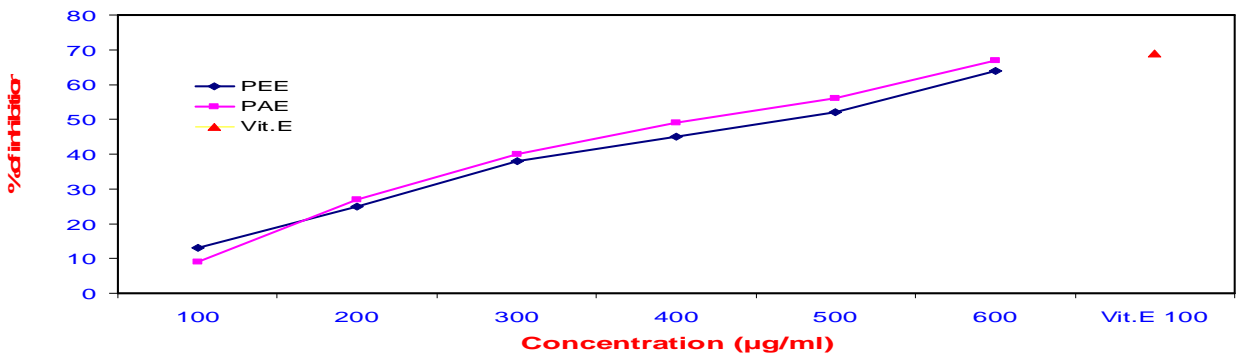
^aP<0.05 when compared with control group (GM)

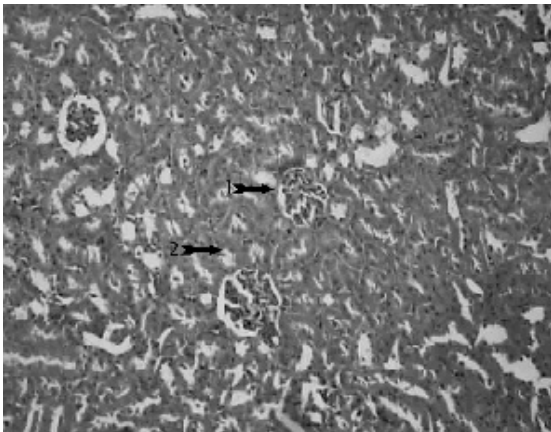
^bP<0.01 when compared with Std group

Fig-10: Percentage inhibition of Nitric oxide scavenging activity of PEE and PAE

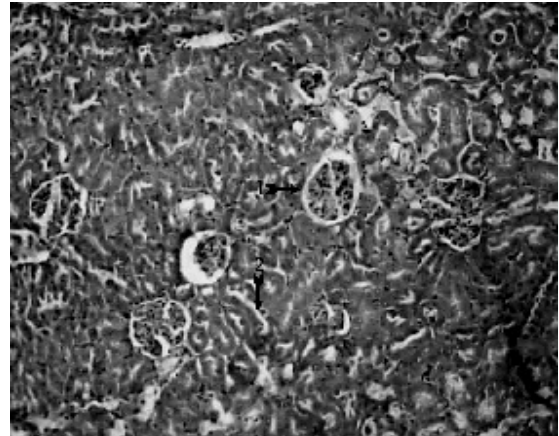


Dfig-11: Percentage inhibition of DPPH activity of PEE and PAE

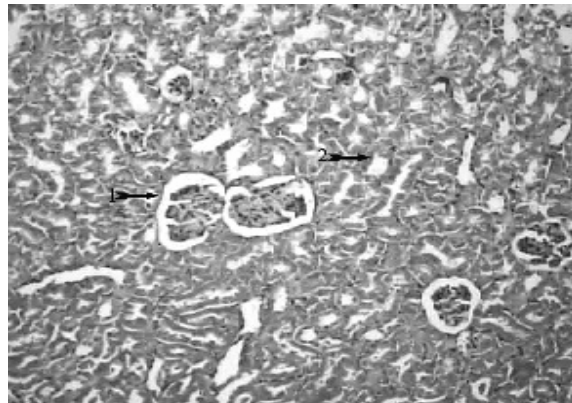




Normal (Fig 1.)



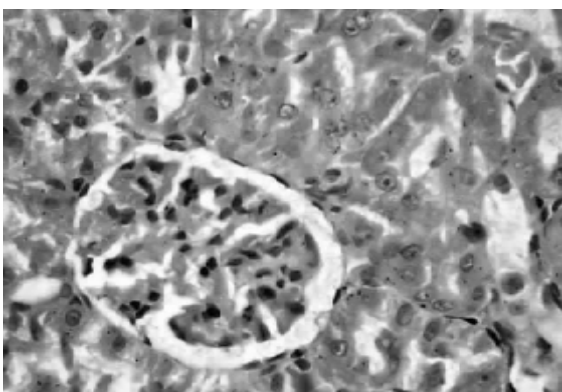
PEE 600 (Fig 2.)



PAE 600 (Fig 3.)

Section of normal, PEE and PAE treated rat kidneys revealing

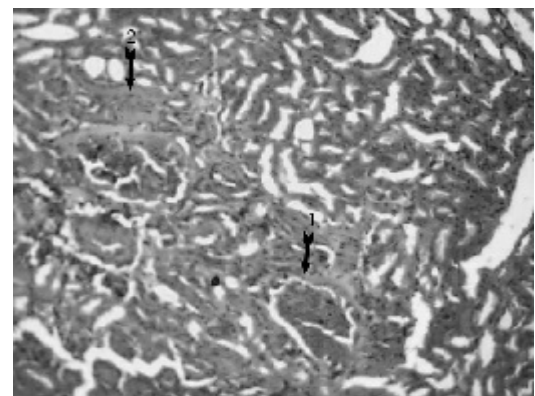
1. Normal orchitecture of glomeruli
2. Normal orchitecture of tubular epithelial cells



(Fig 4.)

((Vit.E+GM): Section of Kidney revealing

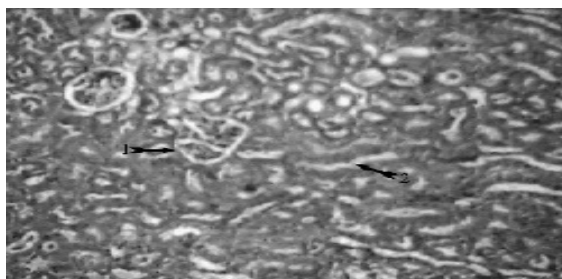
- 1.normal glomeruli
- 2..mild cloudy appearance of tubular epithelial cells



(Fig 5.)

(GM): Section of Kidney revealing

1. Haemorrhages
2. Tubular necrosis and Picnotic nuclei



(Fig 6.)

(PEE+GM): Section of Kidney revealing

1. Normal glomeruli
2. Mild cloudy appearance of tubular (indicating regenerative change) epithelial cells.

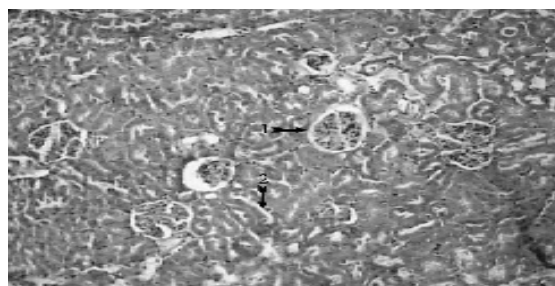
Discussion:

Gentamicin is an aminoglycoside antibiotic commonly used in treating of life threatening gram-negative bacterial infections (Ali, 1995). However 30% of the patients treated with GM for more than seven days show some signs of nephrotoxicity (Mathew., 1992) and serious complications resulting from GM-induced nephrotoxicity are limiting factor for its clinical usage. The exact mechanism by which gentamicin induces the renal damage is unknown, however, evidences suggest a role of reactive oxygen species in this damage; it has been found that O_2^- , H_2O_2 and hydroxyl radicals increase with gentamicin-treatment (Cuzzocrea et al., 2002; Guidet and Shah, 1989; Walker and Shah, 1987,1988; Yang et al., 1995), however, several agents and plants that scavenge or interfere with ROS production successfully ameliorate GM-induced nephropathy (Ademuyiwa et al., 1990; Ali, 2002; Al-Majed et al., 2002; Cuzzocrea et al., 2002; Erdem et al., 2000; Mazzon et al., 2001; Naidu et al., 2000; Nakajima et al., 1994; Pedraza-Chaverri et al., 2000; Sener et al., 2002). *P. murex* is also one such plant containing antioxidant principles and village folk uses this plant to treat renal disorders.

Animals which received plant extracts alone for 8 days, there was no change in serum markers levels, urinary functional parameter levels and antioxidant enzyme levels are same to that of normal animals. These results are supported by histological studies. Hence ethanolic and aqueous extracts of *P. murex* did not show any deteriorative effect on kidney.

Protective effect of ethanolic and aqueous extracts of *P.murex* was tested at 600 mg/kg against GM-induced toxicity. The protective effects of PEE and PAE were compared with vit.E (100 mg/kg) as standard drug.

Results of this study confirmed that gentamicin at a dose of 100 mg/kg produces significant nephrotoxicity as evidenced by increase in blood urea,



(Fig 7.)

(PAE+GM): Section of Kidney revealing

1. Normal glomerular architecture
2. Normal tubular epithelial cells.

serum creatinine, decrease creatinine clearance, excreted high amount of urinary protein and causes renal tubular necrosis.

The success of *P. murex* extracts in reducing SC, BUN, urinary protein excretion and raise in Clcr could be attributed due to its antioxidant properties because of its antioxidant property it reduces the formation of ROS which may be involved in the impairment of GFR (Pedraza chaverri et al., 2000).

GM alone significantly increase in LPO levels while GSH and CAT activities were reduced in the kidney tissue similar results were observed by Ozbek et al., (2000) and Adaihpoh et al., (2007). Co-administration of PEE and PAE (600 mg/kg) caused significantly decreased LPO, increased the levels of GSH and CAT and as similar to that standard drug treated animals (Rana and Verma., 1996). These finding correlated with the renal histological examination which revealed that more extensive and marked tubular necrosis with hemorrhages and picnotic nuclei in the GM treated kidney similar changes were also reported in earlier studies. At 600 mg/kg of aqueous extract (PAE) showed normal architecture of glomeruli and tubular epithelial cells as similar to that of normal kidney and standard drug treated animals.

A relationship between oxidative stress and nephrotoxicity has been well demonstrated in many experimental animal models (Sharaky et al., 2007; Parlak pinan et al., 2005; Alessahin et al., 2003; Karchan et al., 2005). Evidence points out of that GM induce nephrotoxicity via oxidative stress. Hence present study also focused on the nitric oxide scavenging activity and DPPH activity and both of the extracts showed significant activity.

In conclusion, the fruits *Pedaliium murex* had a protective effect against GM induced nephrotoxicity may be through antioxidant property. However further studies are essential to elucidate the exact mechanism of nephroprotector activity.

REFERENCES

- Adaikpoh MA, NEJ Orhue and I. Igbe. The protective role of *Scoparia dulcis* on tissue antioxidant defense system of rats exposed to cadmium. *African Journal of Biotechnology*, 6 (10), 2007, 1192-1196.
- Ademuyiwa O, Ngaha EO, Ubah FO. Vitamin E and selenium in gentamicin nephrotoxicity. Humand and Experimental against gentamicin-induced nephrotoxicity in rats. *Journal of Pineal Research*, 32 (4), 1990, 231-236.
- Ali BH. Gentamicin nephrotoxicity in humans and animals:some recent research. *Gen. Pharmacol.*, 26, 1995, 1477-1487.
- Ali BH. The effect of treatment with the medicinal plant *Rhazya stricta* decne on gentamicin nephrotoxicity in rats. *Phytomedicine*, 9 (5), 2002, 385-389.
- Al-Majed AA, Mostafa AM, Al-Rikabi AC, Al-Shabanah OA. Protective effects of oral arabic gum administration on gentamicin-induced nephrotoxicity in rats. *Pharmacological Research*, 46 (5), 2002, 445-451.
- Atessahin A, Yilmaz S, Karahan I, Ceribasi AO, Karaoglu A. Effects of lycopene against cisplatin-induce nephrotoxicity and oxidative stress in rats. *Toxicology*, 212 (2-3), 2005, 116-123.
- Azhar Alam MM, Kalim Javed MA, Jafri. Effect of *Rheum emodi* (Revand Hindi) on renal functions in rats. *Journal of Ethnopharmacology*, 96, 2005, 121-125.
- Baliga R, Ueda N, Walker PD, Shah SV. Oxidant mechanisms in toxic acute renal failure. *Drug Metab. Rev.*, 31 (4), 1999, 971-997.
- Beauchamp D, Poirier A, Bergeron MG. Increased nephrotoxicityof gentamicin in pyelonephritic rats. *Kidney Int.*, 28, 1985, 106-113.
- Black J, Calesnick B, Williams D, Weinstein MJ. Pharmacologyof gentamicin a new broad-spectrum antibiotic. *Antimicrob. Agents Chemother.*, 5, 1963:138-147.
- Blio MS. Antioxidant determinations by use of stable radical. *Nature*, 181, 1958, 1199-1200.
- Cohen et al. Effect of gentamicin on renal function in the rat. *J. Pharmacol. Exp. Ther.*, 193 (1), 1975, 264-275.
- Cuzzocrea S, Mazzon E, Dugo L, Serraino I, Di Paola R, Britti D, De Sarro A, Pierpaoli S, Caputi A, Masini E, Salvemini D. A role for superoxide in gentamicin-mediated nephropaty in rats. *European Journal of Pharmacology*, 450 (1), 2002, 67-76.
- Ellman G. Tissue sulphhydryl groups. *Arch. Biochem. Biophys.*, 82, 1959, 70-77.
- Erdem A, Gundogan NU, Usubutun A, Kilinc K, Erdem SR, Kara A, Bozkurt A. The protective effect of taurine against gentamicin-induced acute tubular necrosis in rats. *Nephrology Dialysis and Transplantation*, 15 (8), 2000, 1175-1182.
- Godkar PB. Kidney function tests. In:Text book of Medical Laboratory Technology; Bhalani Publishing House, Bombay: 1994, 233-249.
- Green LC, Wagner DA, Glogowski J, Skipper PL, Wishnok JS, and Tannebaum SR. Analysis of nitrate and (15N) nitrate in biological fluids. *Anal. Biochem.*, 126, 1982, 131-38.
- Guidet BR, Shah SV. In vivo generation of hydrogen peroxide byrat kidney cortex and glomeruli. *Am. J. Physiol.*, 256, 1989, F158-F164.
- Humes HD, Weinberg JM, Knauss TC. Clinical and pathophysiologic aspects of aminoglycoside nephrotoxicity. *Am. J. Kidney Dis.*, 2, 1982, 5 -29.
- Karahan A, Atessahin S, Yilmaz AO, Ceribasi F, Sakin. Protective Effect of Lycopene on Gentamicin-Induced Oxidative Stress and Nephrotoxicity In Rats. *Toxicology*, 215, 2005, 198-204.
- Kehrer JP. Free radicals as mediators of tissue injury and disease. *Crit. Rev. Toxicol.*, 23 (1), 1993, 21-48.
- Kumar KV, Shifow AA, Naidu MU, Ratnakar KS. A beta blocker with antioxidant property protects againstgentamicin-induced nephrotoxicity in rats. *Life Sci.*, 66, 2000, 2603-2611.
- Maldonado PD, Barrera D, Rivero I, Mata R, Medina-Campos ON, Hernandez-Pando R, Pedraza-Chaverri J. Antioxidant S-allylcysteine prevents gentamicin-induced oxidative stress and renal damage. *Free Radic. Biol. Med.*, 35, 2003, 317-324.
- Marcocci L, Maguire JJ, Droy-Lefaix MT, and Parker L. The nitric oxide scavenging properties of Ginko Biloba extract EGb 761. *Biochem. Biophys. Res. Commun.*, 201, 1994, 748-755.
- Mathew TH. Drug-induced renal disease. *Med. J. Aust.* 156, 1992, 724-728.
- Mazzon E, Britti D, De Sarro A, Caputi AP, Cuzzocrea S. Effect of N-acetylcysteine on gentamicin-mediatednephropathy in rats. *European Journal of Pharmacology*, 424 (1), 2001, 75-83.
- Naidu MU, Shifow AA, Kumar KV, Ratnakar KS. Ginkgo biloba extract ameliorates gentamicin-induced nephrotoxicityin rats. *Phytomedicine*, 7 (3), 2000, 191-197.
- Nakajima T, Hishida A, Kato A. Mechanisms for protective effects of free radical scavengers on gentamicin-mediated nephropathy in rats. *Am. J. Physiol.*, 266 (3 Pt 2), 1994, 425-431.

- Niazi FR. Influence of PAF antagonist (Ginko biloba) and ACE inhibitors (Captopril and Lisinopril) on gentamicin induced nephrotoxicity in rats. F/O Pharmacy, Jamia Hamdard, New Delhi, 1994.
- Ohkawa H, Ohishi N, Yagi K. Assay for lipid peroxides in animal tissues by thiobarbituric acid reaction. *Anal. Biochem.*, 95, 1979, 351–358.
- Ozbek E, Turkoz Y, Sahna E, Ozugurlu F, Mizrak B, Ozbek M. Melatonin administration prevents the nephrotoxicity induced by gentamicin. *BJU Int.*, 85, 2000, 742–746.
- Panda S, Gupta P, Kar A. Protective role of *Ashwagandha* in cadmium induced hepatotoxicity and nephrotoxicity in male mouse. *Current Science*, 72, 1997, 546–547.
- Parlakpınar H, Tasdemir S, Polat A, Bay-Karabulut A, Vardi N, Ucar M, Acet A. Protective role of caffeic acid phenethyl ester (CAPE) on gentamicin-induced acute renal toxicity in rats. *Toxicology*, 207 (2), 2005, 169–177.
- Pedraza-Chaverrı́ J, Gonzalez-Orozcoa AE, Maldonado PD, Barrera D, Medina-Campos ON, Hernandez-Pando R. Diallyl disulfide ameliorates gentamicin-induced oxidative stress and nephropathy in rats. *Eur. J. Pharmacol.*, 473, 2003, 71–78.
- Pedraza-Chaverri J, Maldonado PD, Mediana-Campos ON, Olivares-Corichi IM, Granados-Silvestre MA, Hernandez-Pando R, Ibarra-Rubio ME. Garlic ameliorates gentamicin nephrotoxicity: relation to antioxidant enzymes. *Free Radic. Biol., Med.* 29, 2000, 602–611.
- Priuska EM, Schacht J. Formation of free radicals by gentamicin and iron and evidence for an iron/gentamicin complex. *Biochem. Pharmacol.*, 50 (11), 1995, 1749–1752.
- Rana SV, Verma S. Protective effect of GSH, vitamin E, and selenium on lipid peroxidation in cadmium-fed rats. *Biol. Trace Elem. Res.*, 51, 1996, 161–168.
- Ray SD, Wong V, Rinkovsky A et al. Unique organoprotective properties of a novel IH 636 grape seed proanthocyanidin extract on cadmium chloride- induced nephrotoxicity, dimethylnitrosamine(DMN)- induced splenotoxicity and mocap- induced neurotoxicity in mice. *Biol. Trace Elem. Res.*, 2, 2003, 637-642.
- Sandhya P, Varalakshmi P. Effect of lipoic acid administration on gentamicin-induced lipid peroxidation in rats. *J. Appl. Toxicol.*, 17, 1997, 405–408.
- Sangeetha D, Sidhu H, Third SK, Nath R. Therapeutic response of *Tribulus terrestris*, aqueous hyperoxalemia in male rats. *Phytotherapy Res.*, 7, 1993, 116-9.
- Sener G, Sehirli AO, Altunbas HZ, Ersoy Y, Paskaloglu K, Arbak S, Ayanoglu-Dulger G. Melatonin protects against gentamicin induced nephrotoxicity in rats. *J. Pineal Res.*, 32, 2002, 231– 236.
- Sharaky Newairy AA, Badreldeen MM, Eweda SM, Sheweita SA, Protective role of selenium against renal toxicity induced by cadmium in rat. *Toxicology*, 242 (1-3), 2007, 160s.
- Silverblatt FJ, Kuehn C. Autoradiography of gentamicin uptake by the rat proximal tubule cell. *Kidney Int.* 15, 1975, 335–345.
- Singh RG, Singh RP, Usha, Shukla KP, Singh experimental evaluation of diuretic action of *Tribulus terrestris* Linn on albino rats. *J. Res edu Ind Med.*, 10, 1999, 19-20.
- Thamanna and Narayana Rao. In : Medicinal Plants of Tirumala, Pub. Sri Prasad VS, E.O., T.T.D., Tirupati 1990, 32.
- Vedavathy S, Mrudula V, Sudhakar A. Tribal Medicine of Chittoor District, A.P., India, Tirupati, Herbal folklore–Research Center, 1997, 140.
- Walker PD, Shah SV. Evidence suggesting a role for hydroxylradical in gentamicin-induced acute renal failure in rats. *J. Clin. Invest.*, 81, 1988, 334– 341.
- Walker PD, Shah SV. Gentamicin enhanced production of hydrogenperoxide by renal cortical mitochondria. *Am. J. Physiol.*, 253, 1987, C495–C499.
- Yanagida C, Ito K, Komiya I, Horie T. Protective effect of fosfomycin on entamicin-induced lipid peroxidation of rat renal tissue. *Chem. Biol. Interact.*, 148 (3), 2004, 139–147.
- Yang CL, Du XH, Han YX. Renal cortical mitochondria are the source of oxygen free radicals enhanced by gentamicin. *Ren. Fail.*, 17, 1995, 21– 26.