



EFFECT OF HYPERGLYCEMIA ON OVARIECTOMY INDUCED BONE LOSS

Chirag Patel, Rangrez Mohammedayaz, Pragna Parikh*

Division of Physiology, Department of Zoology, Faculty of Science, The M. S. University of Baroda, Vadodara 390002, Gujarat, India.

ABSTRACT

Diabetes confers an adverse cardiovascular and osteoporosis risk profile particularly in women after menopause. Fewer studies have offered a rational correlation between these complications in detail. Hence, this study was undertaken to understand the correlation between diabetes and osteoporosis. Female wistar rats were made hyperglycemic using streptozotocin and osteoporotic by performing bilateral ovariectomy. To understand the combined effect, ovariectomized animals were dosed with streptozotocin after the recovery from ovariectomy. Various markers of diabetes and bone loss were studied using hematological and biochemical estimations. Histological analysis was carried out to understand the cellular damage to liver, kidney and bone. Our results showed that hyperglycemia affects bone metabolism, reduces bone formation and promotes bone resorption, leading to net bone loss. It has alarming effect on the markers of bone health like Alkaline Phosphatase and Tartarate resistant Acid Phosphatase. On the other side, we did not find any significant effects of estrogen loss on the markers of diabetes or cardiovascular diseases. Our study provided the insight into the possible effects of hyperglycemia on bone loss and suggested that individuals with hyperglycemia are having rapid bone loss and are more prone to osteoporosis.

Key words: Diabetes, Osteoporosis, Bone.

INTRODUCTION

Osteoporosis is a bone condition defined by low bone mass, increased fragility, decreased bone quality, and an increased fracture risk (WHO, 1994). Osteoporosis is affected by many factors including genetic and environment. It is also affected by prevalence of other diseases such as diabetes, hypertension and obesity. Although osteoporosis traditionally has not been listed as a complication of diabetes, patients with either type 1 or type 2 diabetes are among those at increased risk for this disease. Type 1 diabetes is an autoimmune disorder resulting in loss of pancreatic insulin-producing β -cells that presents in childhood or early adulthood. Along with increased risk of complications including retinopathy, nephropathy, neuropathy, and cardiovascular events, adults with type 1 diabetes have decreased bone mineral

density (BMD) compared with control subjects (Christensen *et al.*, 1999; Kemink *et al.*, 2000). In fact, osteoporosis is the most significant metabolic bone disease in individuals with diabetes (Inzerillo and Epstein, 2004). Patients with diabetes Type 1 have long been associated with low bone density. However, it was unclear until recently whether this translated into increased fracture rates.

Diabetes had been shown to have significant effect on the onset of osteopenia and osteoporosis. This study was established in both animal and human models. In a study by Locatto and his colleagues (1993) it was reported that bone volume of trabecular volume gets affected in alloxan induced diabetic rats. Further, Bain and co workers (1997) reported that this decrease in the bone volume directly correlates with the increase in glycemic levels. Later it was established that diabetes not only affects bone volume or quality of bone, but it also decrease bone mineral content and it is much more

Corresponding Author

Pragna Parikh

Email: *php59@yahoo.com

worsened with the progression of glyceic conditions (Verhaeghe *et al.*, 2000). Among many systemic and local factors involved in the regulation of bone metabolism are insulin, insulin-like growth factor-I (IGF-I) and other cytokines (Canalis, 1993 and Thomas *et al.*, 1997).

In human patients femoral osteoporosis has often been reported as a complication of diabetes. This is particularly true for type I diabetes mellitus and an even higher frequency is likely if metabolic compensation is poor. Patients with diabetes are at risk for osteoporosis and its complications, including hip fracture (Forsen *et al.*, 1999 and Nicodemus and Folsom 2001). Femur neck fractures are significantly more common in diabetics than in normal subjects, while histomorphological studies have shown a significant reduction in their bone trabecular volume and number of marrow capillaries. It is felt that vascular factors, especially augmented capillary permeability caused by the subendothelial alterations associated with diabetes, are the main cause of osteopenia. Work on the rat, however, has suggested that diminished bone mass is more a result of metabolic changes rather than of microangiopathy. A negative calcium balance has also been reported in the diabetes of recent origin. This is the outcome of both enhanced urinary calcium loss and depressed intestinal absorption, itself perhaps a consequence of reduced renal synthesis of 1, 25-dihydroxy vitamin D₃. By contrast, the calcium balance becomes positive and bone turnover is reduced in the chronically diabetic rat, despite hypercalciuria and hyperphosphaturia (Forsen *et al.*, 1999).

Higher glucose levels in the blood are known to interact with several proteins to form advanced glycation end (AGE) products. Yamagishi and his team (2006) hypothesized that AGE-products in collagen may interact with bone to reduce bone strength, resulting in osteoporosis in patients with diabetes. Accumulated AGE-products in the body may stimulate apoptosis of osteoblasts, thereby contributing to deficient bone formation. AGE-products are specifically recognized by AGE receptors (RAGE) (Alikhani *et al.*, 2007). AGE-RAGE interaction is known to alter bone healing and bone turnover processes. Another indirect effect of hyperglycemia is glycosuria, which causes hypercalciuria, leading to decreased levels of calcium in the body and poor bone quality. Additionally, several diabetes-related complications such as retinopathy, neuropathy, and nephropathy have been linked to decreased BMD.

There are still no confirmed reports available regarding the effect of menopausal conditions on the glyceic index and what is the association of it to the onset of osteoporosis. Hence, in the present study an attempt is made to understand the effect of hyperglycemia and related complications on the onset of osteoporosis. With keeping this aim in mind, the first set of the experiment was designed to understand the effect STZ in

ovariectomized wistar rats with comparison to normal progression of diabetes and osteoporosis.

MATERIALS AND METHODS

Healthy adult female Wistar rats (80–90 days old) were maintained in a well ventilated, temperature-controlled room on a 12 h light: 12 h dark schedule. The rats were fed with standard balanced rat pellets (Vadodara., India) and drinking water was made available *ad libitum*.

A bilateral ovariectomy operation was performed to mimic post menopausal conditions in the rats as described previously (Parikh *et al.*, 2009 and Rangrez *et al.*, 2011). Following a lag phase of 15 days, the rats were divided into the following groups:

- (i) Control (C)
- (ii) Ovariectomized (OVX)
- (iii) Streptozotocin induced diabetic (SZD) and
- (iv) Streptozotocin induced diabetic + Ovariectomized.

Each group consisted of 5 rats. All rats were sacrificed on day 30 after the induction of diabetes. The experiments conducted were approved by the Ethical Committee for Animal Research at the Department of Zoology. The rats were sacrificed at the end of 30 days after the induction of diabetes. Blood samples were collected from the rats, and sera were separated and stored at -86 °C for biochemical studies. The tissues were processed for biochemical estimation.

Biochemical assays

Blood glucose, serum calcium were estimated using a commercially available kit (Reckon Diagnostics). ALP and TRAcP activity was estimated using the commercial kits purchased from Reckon diagnostic Ltd. SGOT and SGPT the markers of the liver damage and Urea and Creatinine, markers for the kidney damage were estimated using a commercially available kit (Reckon Diagnostic). Hematological parameters were investigated using Nihon Cohden Automated analyzer (Celltac, Japan).

Histology

For histology, as described by the protocol of Rangrez and his team (2009), immediately after sacrifice, the bone, liver and kidney were harvested and fixed in 4% paraformaldehyde. Bones were then demineralized in 10%EDTA solution and dehydrated using grades of alcohol and embedded in paraffin. The paraffin blocks were then placed in microtome and 5 µm transverse sections were obtained. Both kidney and liver were washed free of excess fixative and dehydrated using grades of alcohol and embedded in paraffin. After deparaffinizing, sections were immersed in the filtered hematoxylin for 3 min and then rinsed with running water until the water became clear. Sections were again immersed in eosin stain for 1-2 min and rinsed until water

became clear. Thereafter these were dehydrated in ascending graded alcohol solutions (50, 70, 80, 95 X 2, 100% X 2 times) and cleared with xylene (3 times) and viewed under the light microscope and photo-documented using canon S 7 camera.

Statistical Analysis

The data was subjected to One way Anova, followed by multiple comparison and analyzed using Graph Pad prism 5. p values < 0.05 was considered significant.

RESULTS

Food, water intake and body weight gain

Table 1 shows food and water intake and body weight gain at the end of the study. Figure 1 shows the food consumption of all the 4 experimental groups. In diabetic animals there was decrease in the food intake. However, there were no significant differences observed between the OVX and hyperglycemic OVX animals. Compared to food intake, there was no significant changes were observed in the water intake of all the animal groups (Figure 2). Body weight was lower in diabetic group compared to control animals. Compared to diabetic animals both OVX and hyperglycemic OVX animals showed significant weight gain. To our surprise, observed body weight gain in hyperglycemic OVX animals was even more than osteoporotic animals (Figure 3).

Hematology

Hematological profile was studied in all 4 groups to understand the effect of these two diseases on the health of the animal (Table 2). Hemoglobin levels showed non-significant fall in Hb levels in both OVX and hyperglycemic OVX rats compared to control (Figure 4). Parallel with these results were the results of RBC count of blood, which showed decrease in OVX animals and further fall in hyperglycemic OVX animals (Figure 5). WBC count in diabetic animals showed significant decrease. Contrary to this, there was an increase in the WBC count in OVX and hyperglycemic OVX animals (Figure 6). No changes were observed in the monocyte count, but there was significant increase in the lymphocyte count in both OVX and hyperglycemic OVX animals (Figure 7 and Figure 8). Polymorph count was lowered in both diabetic and osteoporotic animals, contrary to this, hyperglycemic OVX animals showed increased levels of polymorph count (Figure 9). Similar profile was observed with eosinophil count; however, the data was not statistically significant except for hyperglycemic OVX group (Figure 10). No significant changes were observed in platelet count in any of the group (Figure 11).

Serum biochemical profile

Various markers of diabetes and osteoporosis were studied in this experiment. The results of these findings are expressed in Table 3.

Blood glucose levels

Serum glucose is one of the baseline markers of studying hyperglycemia and its related pathogenesis. As expected, blood glucose levels were found to be higher in diabetic animals. This data was found to be highly significant when compared with control ($p < 0.001$). Parallel results were observed in hyperglycemic OVX animals, which expressed high blood glucose levels. No significant changes in blood glucose were observed in the osteoporotic animals (Figure 12).

Serum Urea and Creatinine Levels

Serum urea is one of the important functional markers of the nitrogen metabolism. Compared to control, there was increase in the urea levels of the diabetic animals. No significant changes in the urea profile were observed in the OVX or OVX hyperglycemic animals (Figure 13). Serum creatinine is the most established marker of kidney functioning. Increase in the serum Creatinine levels indicates the onset of nephropathic condition, which is found to be associated with diabetes and blood pressure like complications. Diabetic animals showed increase in the serum creatinine levels. However, OVX and OVX hyperglycemic animals showed no significant alterations in the creatinine levels (Figure 14).

Serum SGOT and SGPT activity

SGOT or Aspartate transaminase and SGPT or Alanine transaminase are the clinical markers of liver health. Diabetic rats showed a non-significant decrease in serum SGOT activity. Compared to control, OVX and OVX hyperglycemic experimental groups exhibited highly significant decrease in SGOT activity (Figure 15). Serum SGPT was increased in both diabetic and OVX animals. However, contrary to our expectations, OVX hyperglycemic animals did not showed any significant alterations in the serum SGPT activity (Figure 16).

Serum AIP and TRAcP Activity

Serum AIP levels were found to be reduced in the diabetic group, and there was significant increase in the serum AIP levels in both OVX and OVX hyperglycemic experimental groups (Figure 17). Serum TRAcP is a specific lysosomal enzyme secreted by the osteoclastic cells and is a clinical marker of bone resorption. No significant changes were observed in the diabetic group. However, there was almost two fold increase in the OVX and OVX hyperglycemic group, proposing increased activity of osteoclastic bone resorption (Figure 18).

Tissue AIP Levels and TRAcP levels

Bone and liver tissues were taken for assessing the AIP activity. As far as liver is concerned, the diabetic group showed a significant increase compared to the control group, and insignificant alterations were observed in the OVX or OVX hyperglycemic animals (Table 5, Figure 19). Bone AIP level is the end point marker of osteoblastic bone synthesis. We observed no significant alterations in the osteoblast activity in diabetic group. In both OVX and OVX hyperglycemic animals, bone AIP levels were almost doubled, suggesting increased bone synthesis (Table 4, Figure 22). For TRAcP only bone tissue was taken so as to assess the osteoclasts activity. As expected, no significant alterations were seen in diabetic group. However, both OVX and OVX hyperglycemic animals showed increase in this osteoclastic function marker. In OVX group, TRAcP activity was even higher compared to OVX animals (Table 4, Figure 23).

Tissue SGOT/ SGPT levels

Parallel with the serum profile, we observed that there is decrease in the liver SGOT levels of the OVX animals. However, no significant alterations were observed in the diabetic or OVX hyperglycemic animals. Compared to this, liver SGPT levels were higher diabetic animals. Compared to this, OVX and OVX hyperglycemic animals showed decrease in SGPT levels (Table 5, Figure 20 and Figure 21).

Bone calcium content

Bone calcium content is the end point marker of the mechanical strength of the bone. Bone calcium content was reduced in all experimental groups. However, decrease in the diabetic groups was statistically non significant. Compared to this, both OVX and OVX hyperglycemic animals showed significant decrease in the bone calcium content, suggesting weakening of the bones (Table 4, Figure 24).

Histology

To support our biochemical results and to confirm the histological changes, bone, kidney and liver histoarchitectural observations were made H&E stained histological sections of tibial bone showed two major regions, outer compact bone and inner cancellous bone.

Images of the light microscopy were obtained for control (Figure 25), diabetic (Figure 26), OVX (Figure 27) and OVX hyperglycemic (Figure 28) groups. In control, well formed bone histo architecture, with attached bone marrow was observed, showing outer, inner and intermediate bone lamellae. Cancellous bone was formed of a mesh like three dimensional network of bone trabecules. Similar conditions were observed with diabetic group, where no significant signs of bone damage were observable. As expected, OVX animals showed damaged bone trabecules and loosen bone marrow. The number of osteoclastic pits was also higher in OVX group. These signs of osteoporosis were more severe in case of OVX hyperglycemic animals. Cancellous bone was found to be more damaged, and the trabecules were broken, with loss of bone marrow, which might have occurred due to weakened trabecules.

Normal animals showed intact structure of glomeruli as well as the tubules (Figure 29). The diabetic animals showed distorted morphology of the glomeruli as well as the tubules (Figure 30). The renal tubules showed a shrunken nucleus and the glomeruli structure was also damaged compared to the control animals. Altered glomeruli structure is the sign of inflammation. In OVX animals, there were no observable changes, in the histology as compared to control (Figure 31). However, there was vacuolization and swelling in the endothelium of glomeruli. Maximum changes were observed in hyperglycemic OVX rats, where we observed congestion of glomeruli and inflammatory cells and infiltration of lymphocytes in between the tissues and cellular vacuolization (Figure 32).

Control liver histology showed well maintained histoarchitecture of the liver and no signs of damage to the central vein or hepatocytes (Figure 33). Liver histology of the diabetic animals showed hepato-cellular necrosis, leukocyte infiltration with signs of hemorrhage (Figure 34). In OVX rats there were no observable changes in the liver. At very few sites there were alteration in the shapes of the central vein and mild necrosis was observed in the liver (Figure 35). However, major damage was seen in OVX hyperglycemic individuals where cell vacuolation and distortion of the hepatic chords were very distinctly observed (Figure 36).

Table 1. Changes in the body weight, food and water consumption

Parameters	Control	Diabetes	Osteoporosis	Hyperglycemic OVX
Body weight	225 ± 35.66	203 ± 26.15	300* ± 28.36	312*± 39.23
Food intake	43.833 ± 10.882	52.560 ± 7.552	40.596 ± 10.578	43.533 ± 8.245
Water intake	79 ± 25.369	45.133 ± 24.365	33.9 *± 19.456	43.8 ± 22.54

Values were expressed as Mean ± S.E.M. * - $p < 0.05$; ** - $p < 0.01$; *** - $p < 0.001$.

Table 2. showing hematological profile of different groups

Haematological Parameters	Control	Diabetes	Osteoporosis	Hyperglycemic OVX
Eosinophil	9.556 ± 2.366	8.458± 2.154	9.23 ± 1.265	13.569* ± 2.365
Haemoglobin	15.2 ± 0.663	13.55 ± 0.998	15.56 ± 1.223	14.2 ± 1.326
Lymphocyte	32.56 ± 4.89	38.489 ± 6.412	46.55** ± 6.558	50.255*** ± 5.698
Monocyte	25 ± 4.569	24.55 ± 5.458	23.255 ± 6.333	30 ± 7.568
Platelet	5 ± 1.236	4.66 ± 1.25	4.18 ± 2.458	5.41 ± 2.365
Polymorph	39.222 ± 4.698	29 **± 5.212	25.36** ± 2.302	62.455 **± 2.365
Total RBC	6.63 ± 0.898	5.24 ± 0.998	6.74 ± 0.996	6.35 ± 0.886
WBC	2.75 ± 0.233	1.9** ± 0.222	2.8 ± 0.554	2.6 ± 0.232

Values were expressed as Mean ± S.E.M. * - p < 0.05; ** - p < 0.01; *** - p < 0.001.

Table 3. serum profile of different markers of osteoporosis and diabetes

Serum profile	Control	Diabetes	Osteoporosis	Hyperglycemic OVX
Blood glucose	110.666 ± 4.569	379.856*** ± 22.569	128.166 ± 9.788	347.556*** ± 58.69
ALP level	53.79 ± 6.553	48.966 ± 7.255	94.2365*** ± 0.78	86.556*** ± 5.636
Creatinine	0.734 ± 0.12	0.929* ± 0.12	0.774 ± 0.08	0.794 ± 0.05
TrACP	5.4 ± 1.236	5.996 ± 2.596	12.33*** ± 2.59	9.636* ± 2.336
SGOT	75.552 ± 11.232	109.567*** ± 9.586	41.52*** ± 3.45	89.66* ± 4.953
SGPT	17 ± 2.326	39.566 **± 3.265	24.365** ± 2.486	17.458 ± 2.365
UREA	22.123 ± 2.548	29.256 *± 4.567	21.563 ± 5.124	26.487 ± 2.365

Values were expressed as Mean ± S.E.M. * - p < 0.05; ** - p < 0.01; *** - p < 0.001.

Table 4. Showing various parameters in bone tissue

Bone tissue	Control	Diabetes	Osteoporosis	Hyperglycemic OVX
ALP activity	43.833 ± 5.669	48.966 ± 7.098	93.878*** ± 7.48	96.485*** ± 9.563
Bone calcium	23.875 ± 3.669	18.756 ± 5.669	15.886* ± 2.969	14.896** ± 3.559
Bone Tracp	9.859 ± 2.4878	11.986 ± 2.111	16.445* ± 2.969	19.2653** ± 4.996

Values were expressed as Mean ± S.E.M. * - p < 0.05; ** - p < 0.01; *** - p < 0.001.

Table 5. Showing various parameters in liver tissue

Liver tissue	Control	Diabetes	Osteoporosis	Hyperglycemic OVX
ALP	101.36 ± 9.865	132.36** ± 12.569	98.669 ± 8.369	115.596 ± 8.869
SGOT	46 ± 5.1021	43 ± 2.3659	34.111** ± 5.449	51.445 ± 6.559
SGPT	66.235 ± 8.965	210.12*** ± 21.236	49.68 ± 6.235	40.558* ± 6.1125

Values were expressed as Mean ± S.E.M. * - p < 0.05; ** - p < 0.01; *** - p < 0.001.

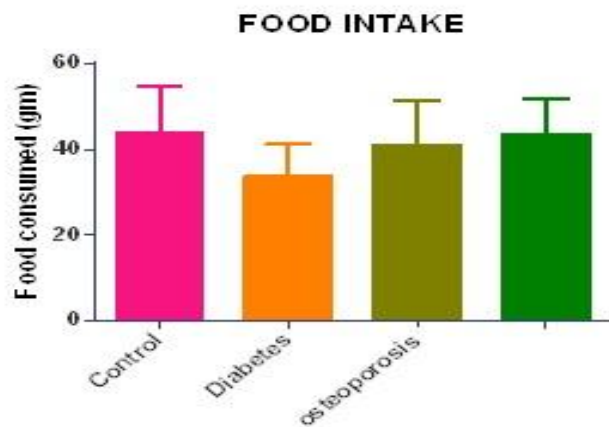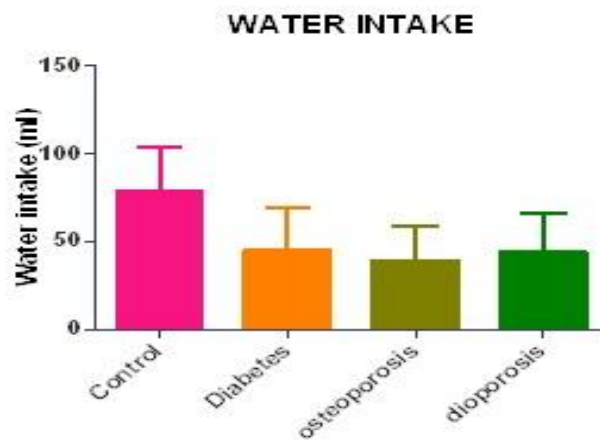
Fig 1. Showing food intake of experimental animals**Fig 2. showing water intake of experimental animals**

Fig 3. Showing Body weight gain in experimental groups

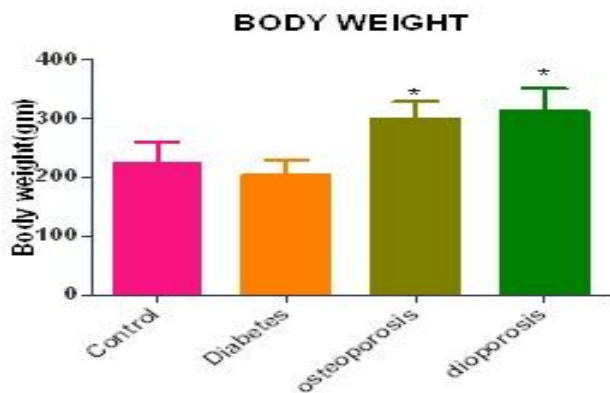


Fig 4. Showing Hemoglobin levels in experimental groups

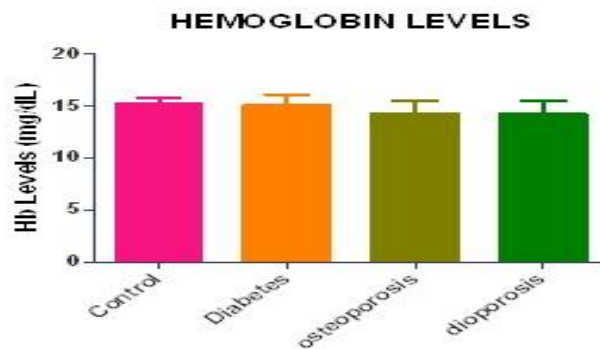


Fig 5. Showing RBC count in experimental groups

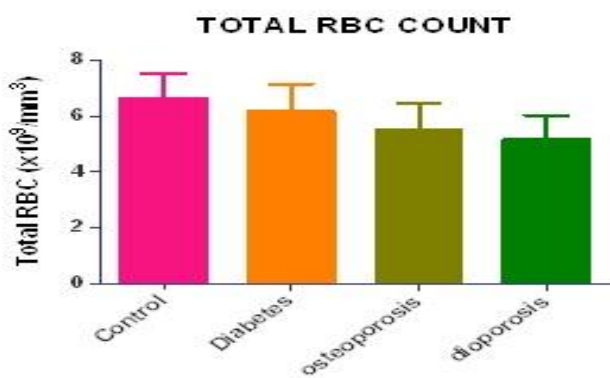


Fig 6. Showing WBC count in experimental groups

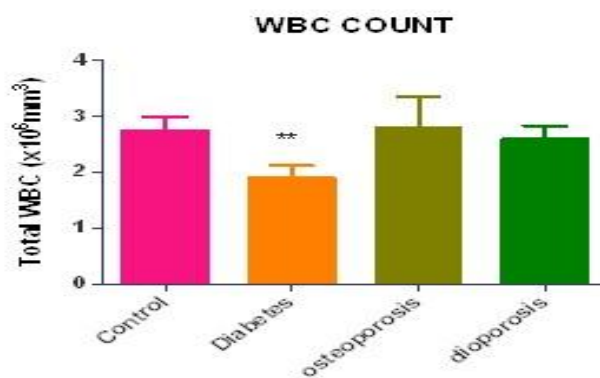


Fig 7. Showing Monocyte count in experimental groups

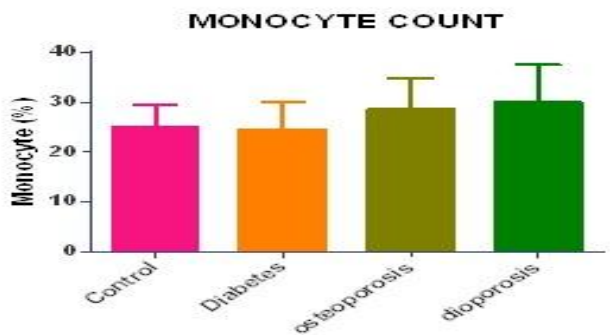


Fig 8. Showing Lymphocyte count in experimental groups

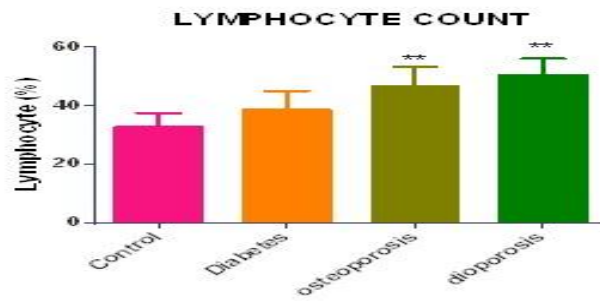


Fig 9. Showing Polymorph count in experimental groups

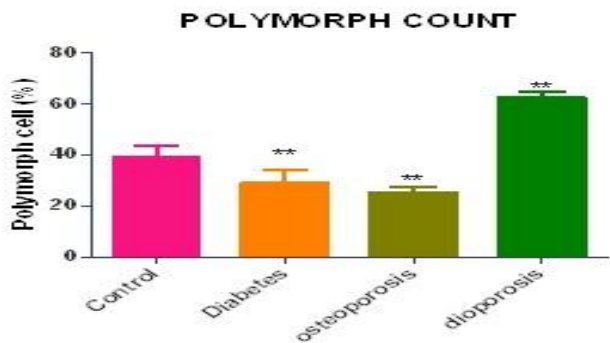


Fig 10. Showing Eosinophil count in experimental groups

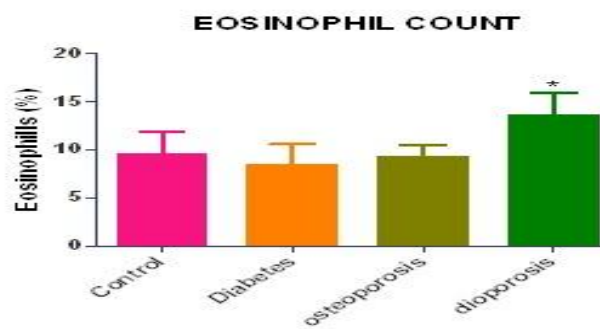


Fig 11. Showing Platelet count in experimental groups

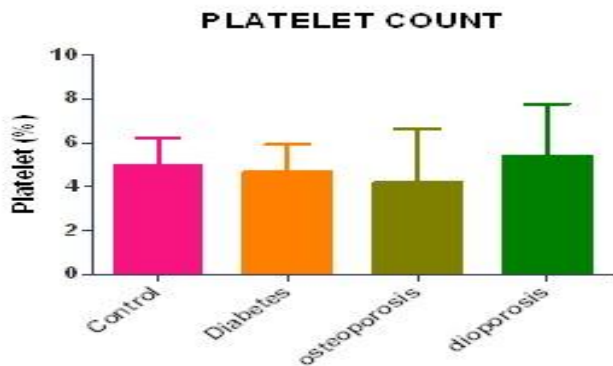


Fig 12. Showing Serum blood glucose levels in experimental groups

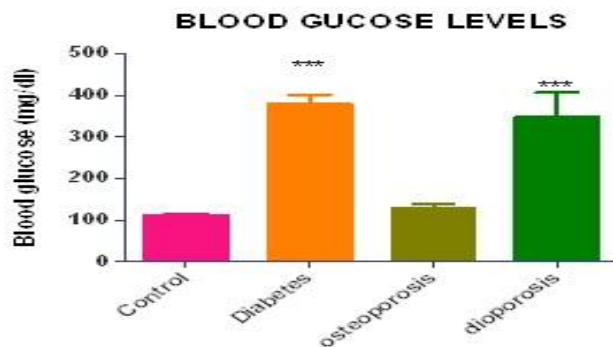

Fig 13. Showing various in Serum urea levels in experimental groups

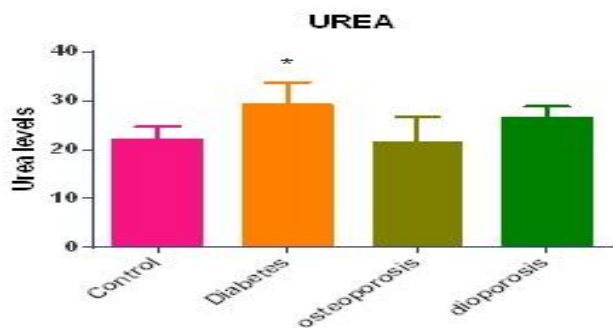


Fig 14. Showing Serum creatinin levels in experimental groups

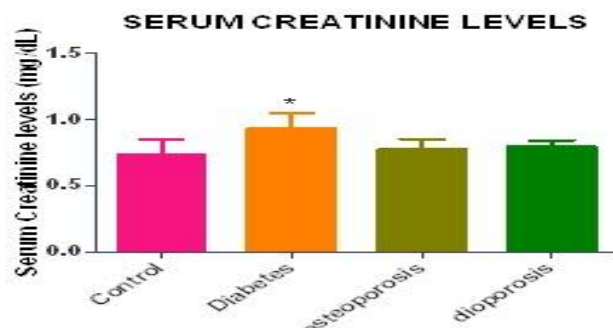


Fig 15. Showing Serum SGOT Activity in experimental groups

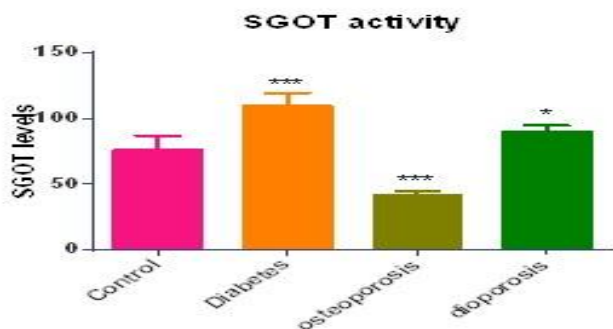


Fig 16. Showing Serum SGPT Activity in experimental groups

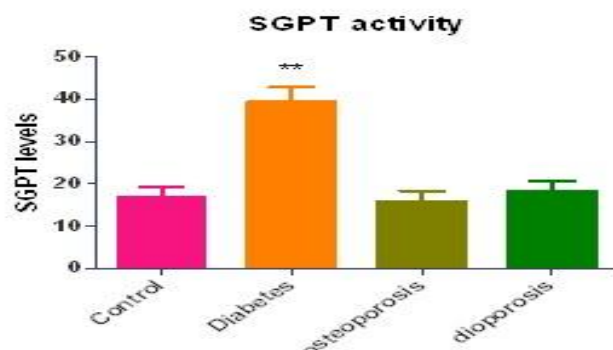

Fig 17. Showing Serum ALP Activity in experimental groups

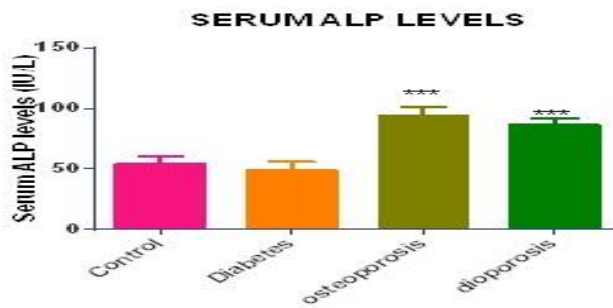


Fig 18. Showing Serum TRAcP activity in experimental groups

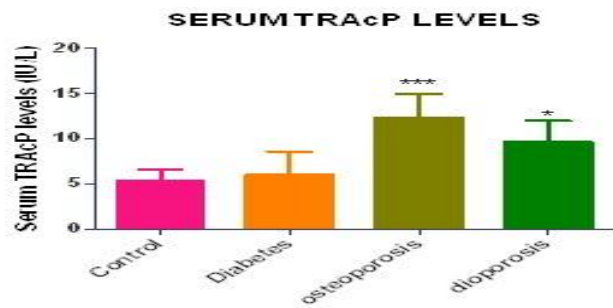


Fig 19. Showing liver ALP Activity in experimental groups

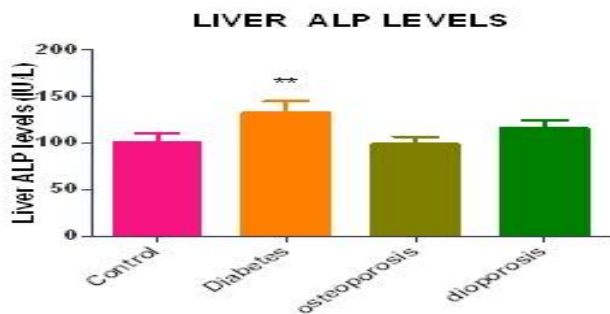


Fig 20. Showing liver SGPT activity in experimental groups

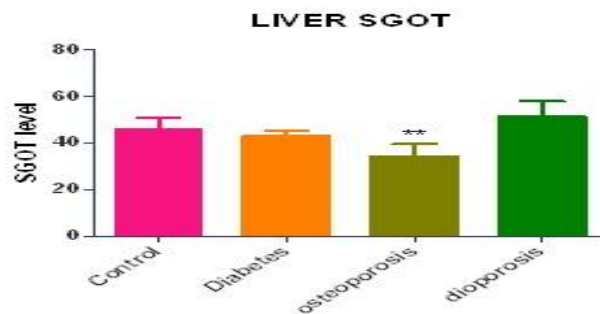

Fig 21. Showing Liver SGPT activity in experimental groups

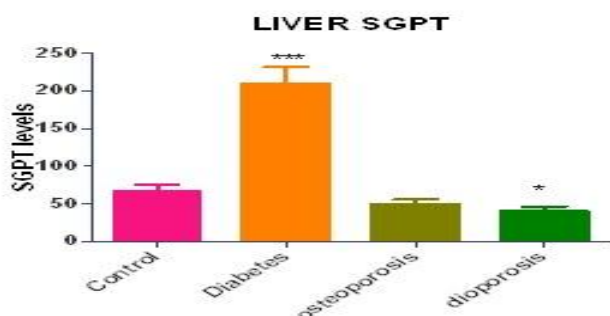


Fig 22. Showing Bone ALP activity in experimental groups

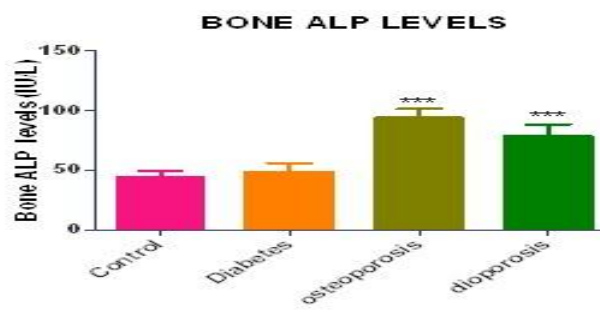


Fig 23. Showing Bone TRAcP activity in experimental groups

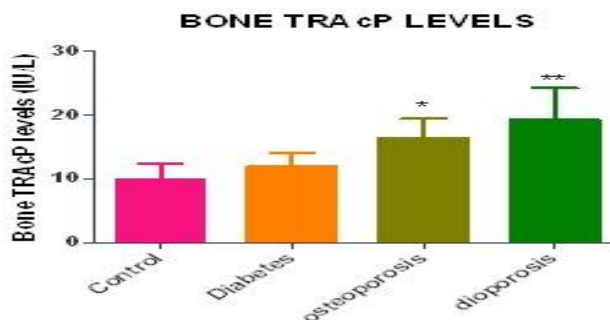


Fig 24. Showing Bone calcium content in experimental groups

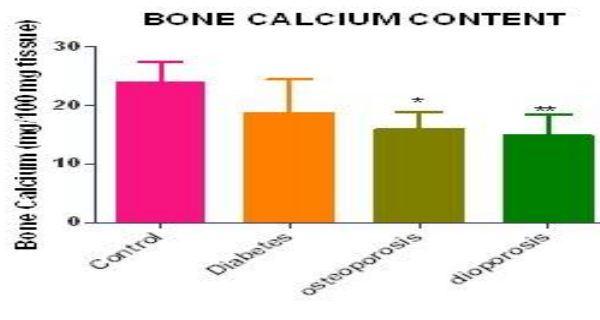


Fig 25. Control bone showing normal histo-architecture, well formed trabeculae and associated bone marrow, **Fig 26.** Diabetic bone showing mild damage to trabeculae and loss of bone marrow. **Fig 27.** OVX bone showing loss of trabeculae, signs of osteoporosis and damaged to trabeculae. **Fig 28.** Hypoglycemic OVX bone showing severe signs of osteoporosis, damage to trabeculae and complete alteration of histo-architecture of the bone.

Fig 25

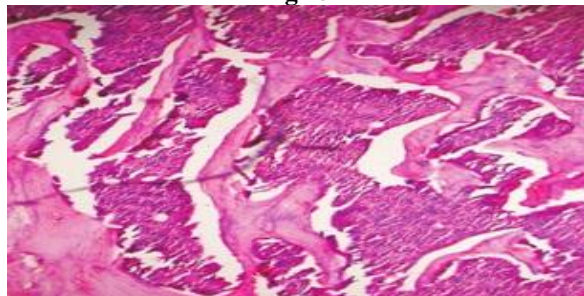


Fig 26

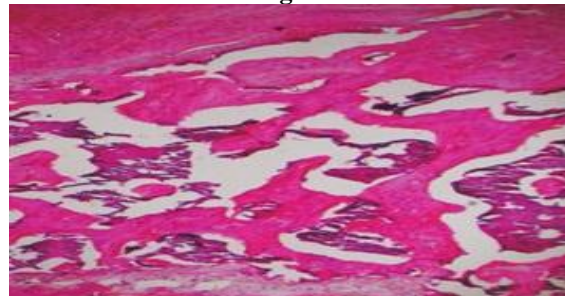


Fig 27

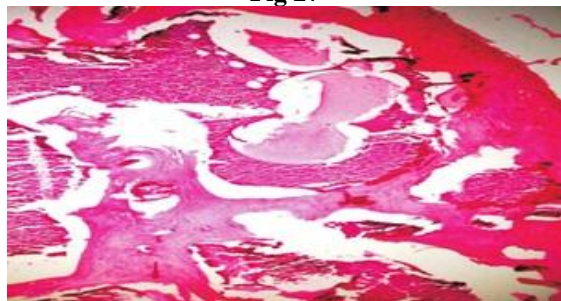


Fig 28

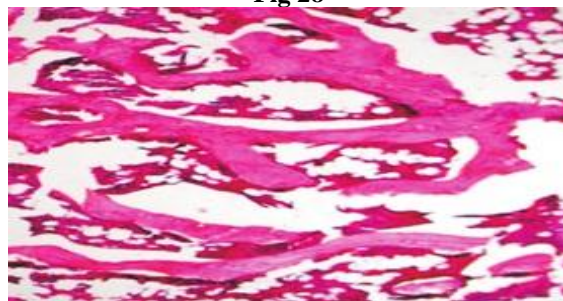


Figure 29. Normal rat sections of kidney showing intact histological structure of glomeruli and tubules **Figure 30.** Diabetic Kidney showed distorted morphology in contrast to that in the control group. The renal tubules lost their intact structure and shrunken lumen was observed. Glomeruli structure was distorted and signs of inflammations were pertinent. **Figure 31.** OVX- showing vacuolization and swelling in the endothelium of glomeruli. **Figure 32.** Hyperglycemic OVX rats showing Congestion of the glomeruli and inflammatory cells infiltration in between the degenerated tubules, showing swelling and vacuolization . Vacuolar degeneration of tubular cells and glomerular congestion

Fig 29

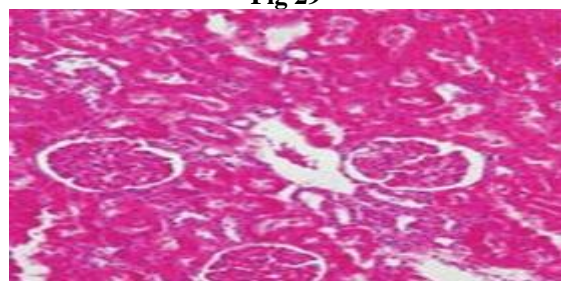


Fig 30

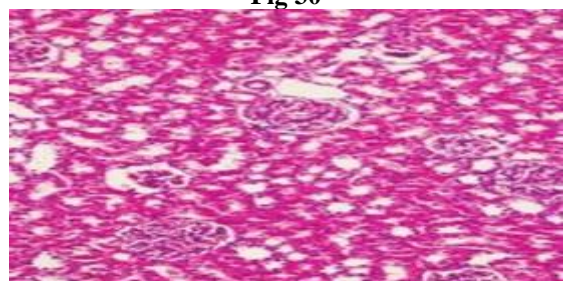

Fig 31

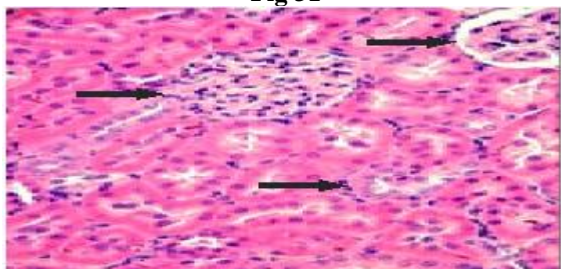


Fig 32

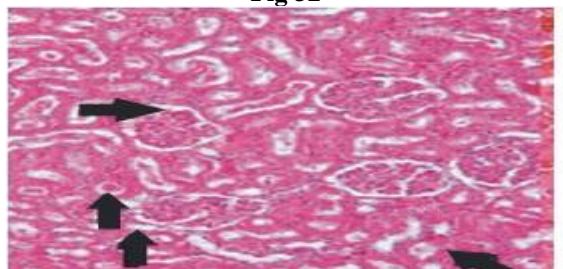


Figure 33. Showing normal histo architecture of liver, with no signs of damage to the central vein or hepatocytes (10X). **Figure 34.** Diabetic liver Showing altered liver histology with hepatocellular necrosis, leukocyte infiltration and massive hemorrhage (10X). **Figure 35.** OVXliver showing congested central veins, swollen and disarranged hepatocytes, with mild necrosis (10X). **Figure 36.** Hyperglycemic OVX liver showing disrupted cords of the hepatic cells, damage and congested central vein (10X).

Fig 33

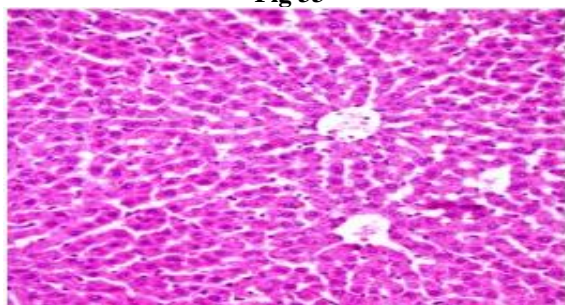


Fig 34

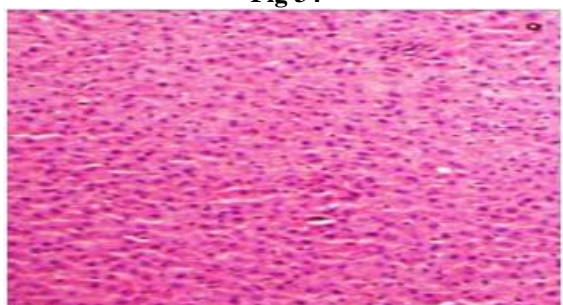


Fig 35


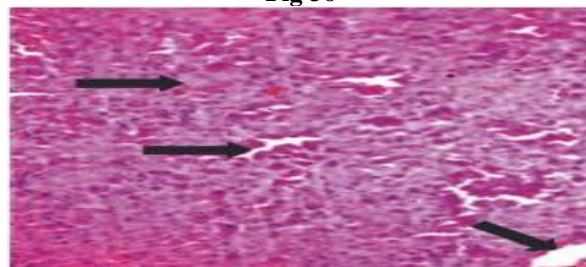


Fig 36



DISCUSSION

Diabetes has been associated with an extensive list of complications involving various tissues in the body, including bone (Bouillon, 1991; Seino *et al.*, 1995; Nicodemus and Folsom, 2001). Previous studies have shown a relationship between diabetes and delayed fracture healing and bone defects in human and animal models (Vestergaard, 2007). Alikhani *et al.*, (2007) in their studies have reported that Alloxan-induced diabetes delays repair in a rat model of closed tibial fracture. However, the possible mechanism behind its effects is still not clearly understood. Our study explores this mystery to its first step and explains that hyperglycemia aggravates bone loss, as it promotes the formation of osteoclastic cells and reduces bone formation, resulting in net bone loss. Induction of bone loss via ovariectomy in rats has been an established model for studying bone loss and associated osteoporosis and it has been validated by various studies. Diabetes associated with estrogen deficiency enhances the bone loss and aggravates bone turn over markers (Gopalkrishnan *et al.*, 2006). The low bone turn over during diabetes and high bone metabolism during menopausal condition may have a contrasting effect on the health of bone during post menopausal diabetic condition. Hence, to understand the complexity of diabetes on bone health, with special reference to post menopausal bone loss, this study was conducted, revealing the effects of hyperglycemia on bone loss.

One of the important features of diabetes is sudden decrease in the body weight. Contrary to this, ovarian function loss leads to weight gain. Similar conditions were observed in our study, where we observed decrease in the body weight of diabetic animals while the OVX animals showed weight gain. However, when the both the effects were combined, the animals showed increase in the body weight. Our results are in agreement with previous reports (Forsen *et al.*, 1999). These results suggest that possibly estrogen loss is having dominating effect over STZ induced hyperglycemia. However, as the body weight depends on variety of factors, one must explore this aspect in detail to develop further understanding.

Hematological parameters did exhibit the alterations however; the changes were not very

significant. The decreased Hb in OVX and OVX hyperglycemic rats suggests an overall anemic condition of the animals and that the animals are in stress and hence a possibility of reduced MCHC and increased MCV and MCH. However, the other related blood indices were not very significant and hence it is difficult to have convinced conclusion. The decreased trend of RBC might be due to the hemolysis and shrinkage of blood cells due to the stress of OVX (Rho *et al.*, 1998) and Hyperglycemia (Thomas *et al.*, 1997).

Urea and creatinine are the bi-products of amino acid metabolism. During diabetic complications, there is an increased possibility of interference with this metabolism. During diabetes there is increase in the serum urea and creatinine levels (Rangrez *et al.*, 2009). Elevated levels of serum urea and creatinine are observed in the present study which may be due to renal damage caused by abnormal glucose regulation or elevated glucose and glycosylated protein tissue levels. The OVX group however did not exhibit any significant alterations in these parameters. Increased activity of both the parameters in the OVX hyperglycemic animals was not significant. This parameter indicates possibilities of deterioration of amino acid metabolic machinery in hyperglycemic OVX animals.

Alanine and aspartate transaminase activities are used as an indicator of hepatocyte damage. Data from the present study showed enhanced Serum SGOT/SGPT activity in the diabetic group. Elevated transaminases activity has been reported previously (Balaban *et al.*, 2009). If the liver functions are getting attenuated by the stress of OVX and hyperglycemia, both the transaminases should show the alterations at the same pace. However, in the present study we could not observe any significant alterations in the liver SGOT or SGPT in these two groups, demanding for further exploration of liver health in hyperglycemic OVX rats.

Parallel with the previous findings, the histological observations in the present study supported our hypothesis and we observed damage to liver and kidney in diabetic and hyperglycemic OVX animals. In diabetic animals the kidneys were found to be exhibiting the phenomenon of glomerular congestion. Previous

workers (Balaban *et al.*, 2009) have already established that diabetes leads to renal damage and prolonged hyperglycemia might result in diabetic nephropathy. Our study confirmed the findings of these previous studies and also showed that hyperglycemia affects glomerulus, damages the parenchyma and leads to vacuolar degeneration of tubular cells (Balaban *et al.*, 2009). However, in hyperglycemic OVX animals, kidney showed glomerular congestion and associated degeneration of tubules were observed. This damage was more severe compared to diabetic group. Liver is an important site for metabolism and storage of glucose. Diabetes and associated hyperglycemia is established to have catastrophic effects on liver health. In our study, we observed hepatocellular necrosis in diabetic animals, along with leucocyte infiltration and hemorrhage. Our results were in concordance with the findings of the previous studies (Thomas *et al.*, 1991; Kemkin *et al.*, Balaban *et al.*, 2009). However, the histological observations of hyperglycemic OVX individuals were not clear, as we observed cell vacuolation and disruption of cords of hepatic cells in these animals. In liver, the OVX hyperglycemic animals were having less intensity compared to diabetic group. These results were confusing and further studies are required to understand these changes and their correlation with hyperglycemia and estrogen absence.

AIP and TRAcP are the most useful markers of studying bone formation and bone resorption, respectively (Rangrez *et al.*, 2009; Rangrez *et al.*, 2011). It has been well documented that increase in serum TRAcP is associated with bone resorption and increased osteoclastic activity (Rangrez *et al.*, 2009; Parikh *et al.*, 2009; Rangrez *et al.*, 2011). Increased TRAcP levels have been well documented in the blood of patients with osteoporosis (Rico and Villa 1993), bone metastases in cancer (Wada *et al.*, 1999), hyperthyroid bone disease, and Paget's disease (Rico and Villa 1993). Our findings supported the previous studies and showed increase in the TRAcP levels in OVX rats. Parallel with these results OVX hyperglycemic animals also showed the increase in the TRAcP activity parallel to the observations made by Kawamoto and his team (2002). Furthermore, the increased TRAcP indicates aggravated osteoclasts activity and elevation bone resorption.

Increased AIP activity indicates osteoblastic activity; in the present study we observed the same in OVX rats. Higher AIP level in the OVX rats have been correlated with the increased bone turnover rate (Rangrez *et al.*, 2009; Parikh *et al.*, 2009; Rangrez *et al.*, 2011), elevated AIP activity thereby suggests an increase in the bone turnover rate. These results are in agreement with previous workers (Rangrez *et al.*, 2009; Parikh *et al.*, 2009; Rangrez *et al.*, 2011), who demonstrated that bone remodelling in rats is accelerated after ovariectomy. It has

been previously reported that IGF-1 levels are reduced in absence of insulin, affecting many physiological processes. However, it was not established about proliferation of osteoblastic cells from pre-osteoblastic cells. Our study confirmed these results and showed that in diabetic condition, there is decreased osteoblastic activity, and associated decreased bone formation. Further confirmation to these findings was offered by bone calcium content measurement, which expressed lower mineral content in the bone of OVX hyperglycemic animals.

In OVX hyperglycemic animals, on one end there is increased osteoclastic activity while on the other hand there is decreased osteoblastic activity. Increased osteoclastic bone resorption may be attributed to increased production of various cytokines, as established by previous studies. In addition, it has already been established long back that STZ induced diabetic rats show decreased osteoblast number and reduction in production of osteoid (Goodman and Hori 1984). Recent studies by Botolin and McCabe (2007) proved that insulin absence leads to suppression of osteoblastic markers, with relative IGF-1 deficiency, leading to poor bone mass and bone mineral density. Hence, on one end where the diabetic condition is leading to more vigorous osteoclasts which increase the bone resorption, at the other end, probably because of the absence of IGF-1 and other growth factors, osteoblastic cells are no more able to keep up with increased bone resorption. This imbalance in the osteoblast and osteoclasts activity leads to demolition of the bone. This is the probable reason why we observed worsened bone health in case of OVX hyperglycemic animals, where the bone mineral content was also reduced.

Parallel with these biochemical findings were the results of histology where we observed altered bone histo-architecture. In OVX animals we observed thinning of bone trabecules and loss of bone marrow. Previous studies by Shaker and his colleagues (2005) and Parikh and her co workers (2009) have also shown similar results and proved that OVX leads to bone loss and maximum damage is seen at the bone trabecules. It is now well established that estrogen plays its role in bone metabolism through secretion of osteoprotegerin. In absence of estrogen, there is aggravated osteoclastogenesis, leading to more bone resorption. These results were marked in the light microscopy, where the thinning of trabecules was observed. Osteoclastogenesis is a complex process, involving production of various inflammatory cytokines. During hyperglycemia, there is increased production of various cytokines and hence, it leads to a larger population of osteoclastic cells. On the other hand, hyperglycemia reduces release of IGF-1 like growth factors and proliferation of osteoblastic cells from mesenchymal stem cells. This leads to a drastic alteration

in the normal ratio of osteoclastic bone resorption and osteoblastic bone formation, leading to more damage to bone, thinning of trabecules and loss of bone marrow in OVX hyperglycemic animals. Our study proved this hypothesis and showed that bone histo-architecture gets worsen in the case of hyperglycemic OVX animals.

Because of the lack of clear data, there is still no clear picture available regarding the possible mechanism behind the loss of bone in hyperglycemic OVX

individuals. Our study tries to justify the possible physiological alterations. Our study showed that hyperglycemia affects bone metabolism, reduces bone formation and promotes bone resorption, leading to net bone loss. However, on the counter side, loss of estrogen was not found to be having any significant effects on the markers of diabetes. Further studies are needed to understand the connection of these two diseases and develop strategies for their cure.

REFERENCES

- Alikhani M, Alikhani Z, Boyd C *et al.*, Advanced glycation end products stimulate osteoblast apoptosis via the MAP kinase and cytosolic apoptotic pathways. *Bone*, 40, 2007, 345-353.
- Bain S, Ramamurthy NS, Impeduglia T, Scolman S, Golub LM and Rubin C. Tetracycline prevents cancellous bone loss and maintains near-normal rates of bone formation in streptozotocin diabetic rats. *Bone*, 21, 1997, 147-153.
- Balaban DTJ, Robert AH, Stephanie F, Angel A and Robert S. Proteomic changes associated with diabetes in the BB-DP rat *Am J Physiol Endocrinol Metab*, 296, 2009, E422-E432.
- Botolin S and McCabe LR. Bone loss and increased bone adiposity in spontaneous and pharmacologically induced diabetic mice. *Endocrinology*, 148, 2007, 198-205.
- Bouillon R. Diabetic bone disease. *Calcif Tissue Int*, 49, 1991, 155-160.
- Canalis E. Insulin-like growth factors and the local regulation of bone formation. *Bone*, 14, 1993, 273-276.
- Christensen J, Svendsen O. Bone mineral in pre- and postmenopausal women with insulin-dependent and non-insulin dependent diabetes mellitus. *Osteoporos Int*, 10, 1999, 307-311.
- Forsen L, Meyer HE, Midthjell K and Edna TH. Diabetes mellitus and the incidence of hip fracture: Results from the Nord-Trondelag Health Survey. *Diabetologia*, 42, 1999, 920-925.
- Goodman WG and Hori MT. Diminished bone formation in experimental diabetes. Relationship to osteoid maturation and mineralization. *Diabetes*, 33, 1984, 825-831.
- Gopalakrishnan V, Arunakaran J, Aruldas M and Srinivasan N. Effects of streptozotocin-induced diabetes mellitus on some bone turnover markers in the vertebrae of ovary-intact and ovariectomized adult rats. *Biochem. Cell Biol*, 84, 728-736
- Inzerillo A, Epstein S. Osteoporosis and diabetes mellitus. *Rev Endocr Metab Disord*, 5, 2004, 261-268.
- Kemink SA, Hermus AR, Swinkels LM, Lutterman JA, Smals AG: Osteopenia in insulin- dependent diabetes mellitus; prevalence and aspects of pathophysiology. *J Endocrinol Invest*, 23, 2000, 295-303.
- Locatto ME, Abranzon H, Caferra D, Fernandez M, Alloatti R and Puche RC. Growth and development of bone mass in untreated alloxan diabetic rats: Effects of collagen glycosylation and parathyroid activity o bone turnover. *Bone Miner.*, 23, 1993, 129-144.
- Mosekilde L, Neck-Nielson H, Sorensen OH, Nielsen SP, Charles P, Vestergaard P *et al.*, Hormonal replacement therapy reduces forearm fracture incidence in recent postmenopausal women – results of the Danish osteoporosis prevention study. *Maturitas*, 36, 2000, 181-193.
- Nicodemus K, Folsom A: Type 1 and type 2 diabetes and incident hip fractures in postmenopausal women. *Diabetes Care* 24:1192-1197, 2001.
- Parikh P, Suresh B and Rangrez A. Osteoprotective effect of *Litsea glutinosa* in ovariectomized wistar rats. *Electronic Journal of Pharmacology & Therapy*, 2, 2009, 81-86.
- Rangrez A, Suresh B and Parikh P. A new technique for studying osteoporosis in Rat Bone: Comparison with Histology and Scanning Electron Microscopy. *Journal of Bionano Frontier*, 3(1), 2009, 74-76.
- Rangrez AY, Suresh B and Parikh PH. Osteoprotective effect of three anti inflammatory plants in ovariectomized wistar rats. *Pharmacologyonline*, 1, 2011, 675-684.
- Rho JY, Kuhn-Spearing L & Zioupos P. Mechanical properties and the hierarchical structure of bone. *Medical Engineering & Physics*, 20, 1998, 92-102.
- Rico H, Relea P, Crespo R, Riivilla M, Villa LF, Arribas I, Usabiaga J. Biochemical markers of nutrition in type-i and type-ii osteoporosis. *The journal. Of bone and joint surgery*, 77, 1995, 148-151.
- Shaker SM, Mohamed GF, Saleh HAA and Seif AAM. Histological study on the effect of calcium supplementation in prophylaxis and treatment of osteoporosis in ovariectomized rats. *The Egyptian Journal of Histology*, 28(2), 2005, 191-198.
- Thomas DM, Hards DK, Rogers SD, Ng KW & Best JD. *Endocrinol. Metab. Clin. North. Am.*, 4, 1997, 5-17.

- Wada N, Ishii S, Ikeda T, Enomoto K and Kitajima M. Serum tartrate-resistant acid phosphatase as a potential marker of bone metastasis from breast cancer. *Anticancer Res.*, 19, 1999, 4515-4521.
- WHO. Assessment of fracture risk and its application to screening for postmenopausal osteoporosis. Report of a WHO Study Group. *World Health Organization technical report series*, 843, 1994, 1-129.
- Yamagishi S, Nakamura K, Inoue H. Possible participation of advanced glycation end products in the pathogenesis of osteoporosis in diabetic patients. *Med Hypotheses*, 65, 2005, 1013-1015.